

## C A S E R E P O R T

# Management and effect of platelet-rich plasma on wound healing: small reality of Oglio Po Hospital

*Fioralba Follo<sup>1</sup>, Dario Oliver Dejana<sup>2</sup>, Marzia Belletti<sup>1</sup>, Nicolina Bongiovanni<sup>1</sup>, Giuseppina Scarpa<sup>1</sup>, Patrizia Pezzali<sup>1</sup>, Sandra Borsi<sup>2</sup>, Laura Sanfilippo<sup>1</sup>, Nadia Lusetti<sup>1</sup>, Luigi Zaini<sup>1</sup>, Patrizia Loritto<sup>1</sup>, Francesco Pogliacomì<sup>2</sup>, Alessio Pedrazzini<sup>1</sup>*

<sup>1</sup> Orthopaedic Unit, Oglio Po Hospital, Vicomoscato (CR), Italy; <sup>2</sup> Orthopaedics and Traumatology Clinic, Department of Surgical Sciences, University of Parma, Parma

**Abstract.** Platelet Rich Plasma (PRP) represents a relatively new approach in regenerative medicine. Its use is increasing in the treatment of a variety of orthopedic conditions, such as the management of acute wounds, chronic non-healing lesions, acceleration of bone formation, tendinopathy and chondropathy. The Orthopaedic Unit at Oglio Po Hospital uses PRP Gel in wound care since 2008. More than 70 patients have been treated with this procedure. The aim of this study is to show our patients outcome. We present 3 cases of severe traumatic wound treated with our PRP protocol. The patients had complete healing of the lesion with good aesthetic results.

**Key words:** Platelet rich plasma, Platelets, growth factors, wound healing, PRP

## Introduction

The Platelet-rich plasma (PRP) is an autologous concentration of human platelets that is 3 to 5 times greater than physiologic concentration of thrombocytes in whole blood (1). Normal platelet count in healthy person ranges between 150000 and 350000 cell/ $\mu$ L of blood. Thrombocytes are usually associated with their primary function in hemostasis and coagulation. After injury with resulted bleeding, thrombocytes are activated and start to release granules filled with growth factors which finally stimulate the inflammatory cascade and healing process. Various proteins and other substances necessary for tissue repair and healing process are secreted by three types of granules (alpha, delta and lambda) located inside the platelets.  $\alpha$ -granules are the most abundant platelet granules. They constitute approximately 10% of platelet volume (more than 300 soluble proteins are released). Generally, functional properties of PRP are mainly based on

the synthesis and secretion of multiple growth factors that are secreted after platelet activation. The prominent growth factors of PRP include platelet-derived growth factor (PDGF), transforming growth factor  $\beta$  (TGF- $\beta$ ), vascular endothelial growth factor (VEGF), epidermal growth factor (EGF), insulin-like growth factor (IGF) and fibroblast growth factor (FGF) (2-4).

The PRP represents a relatively new approach in regenerative medicine. The main application of PRP are in Diabetic and vascular ulcers, in maxillo-facial and plastic surgery and dentistry. Its use is increasing in the treatment of a variety of orthopedic conditions, such as the management of acute wounds, chronic non-healing lesions, acceleration of bone formation, tendinopathy and chondropathy (5-7).

There are various protocols for PRP which is generally is obtained by a blood draw or by apheresis. It has a defined platelet content and a variable volume depending on the type of use; it can be of autologous or allogenic. The blood must be stored for preserva-

tion at temperatures between  $-18^{\circ}\text{C}$  and  $-25^{\circ}\text{C}$  for a maximum of three months, or storage at  $-25^{\circ}\text{C}$  for a maximum of two years (8).

The preparation of PRP is done in two steps: initially the patient's blood is centrifuged to separate the plasma from the corpusculated part (red blood cells), then centrifuged to separate the PRP from the platelet poor plasma (PPP). This concentrate is then activated by adding thrombin or calcium, obtaining platelets gel. In Italy PRP preparation and distribution is managed by transfusional centers. Oglio Po Transfusion Center has already premade PRP bags to promptly respond to department requests, if patient blood type is not known the zero type is available. Thanks to this organization the doctor after prescription can get the Platelets bags within half an hour from the request (the time it takes to thaw the PRP bags).

Oglio Po Hospital has since 2008 a therapeutic-assistance pathway for all traumatic wounds with loss of substance. We built a checklist to clarify the steps, the actors and the responsibilities for PRP application (Table 1). There are 3 important steps: request to the transfusion center, preparation of the wound and PRP application, management of the dressing and follow-up.

At first it is necessary a proper request to the transfusion center; the Nurses pick up the PRP kit composed by a Platelet, an infusion set, three serum tubes with thrombin (Figure 1A).



**Figure 1.** PRP kit (A), PRP Gel (B)

For the application are necessary a sterile field, anatomic plier, sterile gauzes, emesis basin and two syringes. The wound must be cleaned with saline and should not present areas of necrosis, infection and exudate. Once the wound is ready you prepare the PRP GEL. After pouring the platelets into the emesis basin using the infusion set, you aspirate with two syringes the thrombin serum and the gluconate calcium (the amount of glutamine and calcium is calculated on

**Table 1.** PRP Check-List at Oglio Po Hospital

		Doctor	Nurse
Request to the Transfusione Center	Informed Consent by the patient	X	
	Request of Blood Components	X	
	Blood grouping/Typing		X
	Contact the Transfusion Center	X	X
	Blood Components withdrawal and check		X
Wound preparation	Surgical debridement (if necessary)	X	
	Cleaning of the wound		X
	PRP Gel Preparation		X
	PRP Gel Application		X
Dressing Follow-up	Scheduling of dressing / New PRP Application (if necessary)		
	Dressing		X
	Home Care Education		X

platelets volume). After you pour the 2 syringes into the emesis basin and gently shake the bowl in order to mix platelets, thrombin and calcium gluconate and wait 3-5 minutes until a gelatinous substance is formed (Figure 1B).

PRP gel is detached using an anatomical plier, and is applied covering all the wound surface. Finally, Transparent Film Dressing (Tegaderm™) is applied and covered by gauzes and patches.

The doctor schedule the following appointments, usually a new dressing is performed after 3 days by nurses with low adhesion gauzes (Mepitel®, Adaptic™ or Atrauman®). After other three-six days the Doctor evaluate the possibility of another application of platelet gel with the same procedure, otherwise nurses proceed with regular dressing until the complete healing.

## Case Report

Orthopedic UO of Oglio Po Hospital uses the PRP Gel since 2008 for different purpose:

- more than 100 patients have been treated for joint infiltration such as epicondylitis, chronic patellar/Achilles tendinopathy and plantar fasciitis;
- approximately 50 patients have been treated with intraoperative PRP (femoral and tibial osteotomies, LCA reconstruction, osteosynthesis with bone loss, nonunion and pseudo arthrosis);
- approximately 70 patients with traumatic lesions with soft tissue loss or complicated wounds in patients with poor healing with positive outcome and healing of the lesion.

From 2012 this process has been systematically documented by nurses.

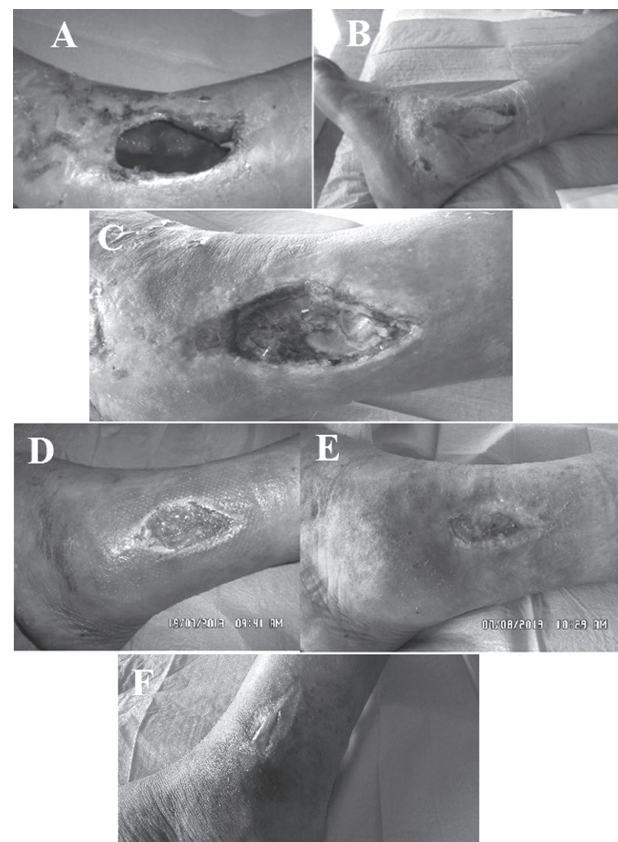
The aim of this study is to show patients outcome treated with this procedure by the Orthopedic Department of Oglio Po Hospital. We present 3 cases of severe traumatic wound treated with our PRP protocol. The patients had complete healing with good aesthetic results.

The first case is direct trauma of the left external malleolus of a biker. After 14 days, the area showed areas of skin necrosis and ischemic suffering. The Orthopedic surgeon decided for PRP application. At

the day of the first dressing hematoma was evacuated and surgical debridement of the lesion was performed (Figure 2A).

The cavity was filled with PRP (Figure 2B) and the area was sealed with a transparent film dressing. The second check-up was after three days (Figure 2C) the wound presented a good engraftment of PRP; the lesion and the edges were gently cleaned with physiological paying attention not to remove the Gel. A secondary dressing with low adhesion gauzes was applied and wrapped in cotton and self-adhesive bandage.

The action of the platelet gel on the wound creates on the bottom a yellow tissue that could be misunderstood as either fibrin or slough (soft necrosis); its removal by surgical debridement leads to failure of treatment. The PRP gel must be left in place for all the duration of the treatment. The goal is filling the loss of substance, sometimes another application, above the



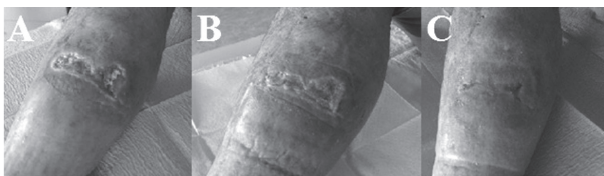**Figure 2.** First dressing: wide injury after debridement (A); then application of the platelet gel (B); Second dressing (C); follow-up at 5 weeks (D); follow-up at 7 weeks (E); Last dressing (F)

previous, is necessary. In this case the timing follows the 3 + 3 + 3 scheme: initial evaluation at time 0 with the first application, reevaluation after three days with new dressing, reevaluation after 3 and 6 days, with possible new PRP application.

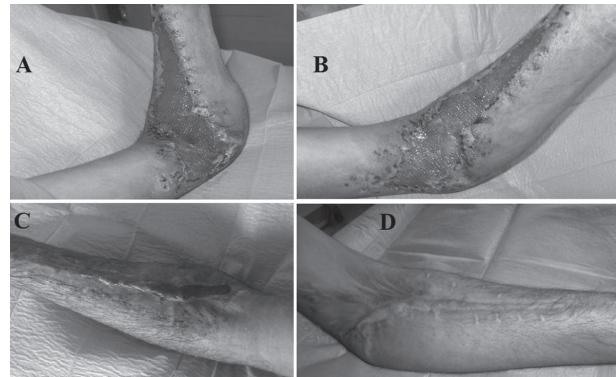
In this case the patient received 4 applications, one every 10 days. After five weeks of treatment, we had great reduction of the lesion, the presence of vital granulation tissue, the healing of the edges with the beginning of re-epithelization (Figure 2D). Another noticeable reduction of the wound size and approaching of the edges was after 7 weeks (Figure 2E). In 98 days and 14 medications at 3-6 days intervals, the lesion was completely closed (Figure 2F).

The second case is a cow kick injury to the anterior region of the tibia of a farmer. After almost 8 weeks from the trauma the patient was evaluated by the Orthopedic Surgeon who detected a healing delay of the lesion. Debridement was performed and he had a first and unique Gel application. After three days, the lesion showed granulation tissue and at the two-weeks check-up we noticed a clear bottom and reduced edges. After 105 days from the trauma, 8 medications at 7-day intervals, the lesion was healed (Figure 3).

The third case is a wide wound of the forearm in a young man after a car accident. The patient sustained fracture of the proximal ulna with soft tissue loss. The lesion was followed by an initial compartment syndrome. After 19 days the wound was dry with regular edges and initial presence of granular tissue at the bottom so we decided for PRP application (Figure 4A). At two weeks check-up the lesion was red-colored with well-defined edges and reduced limb edema (Figure 4B). After physiological saline cleaning, we had to apply low adhesion gauze and zinc paste bandage in order to reduce excessive granulation. About 45 days after trauma the patient had bacterial infection of the



**Figure 3.** Evolution of injury: day 0 (A), 2-week follow-up (B), final 4-week follow-up (C)



**Figure 4.** First dressing: wound with extensive soft tissue loss (A); Two-week follow-up (B); 8-week follow-up (C); 20-week follow-up (D)

wound with positive swab for *Staphylococcus aureus* but with no indications for topical antibiotics so we continued regular dressings. After two months just mild exudate was left but with vascularized edges and no more sign of contamination (Figure 4C). After 146 days, the lesion was fully healed with abundant scar tissue (cheloid) (Figure 4D).

## Discussion and conclusion

In recent years interest in blood components has considerably increased, leading to the explosion of studies and literature in the most disparate areas of clinical medicine. With this great disparity between study designs it is hard to draw conclusions but the ability of PRP to accelerate the process of healing has however been proved (9). A faster healing reduces hospitalization time, improves the quality of life as well as the costs incurred by the community; moreover, some authors (10) suggest a prophylactic use for surgical wounds prone to poor healing because premature application of the platelet gel in these patients avoids chronicization and complications (such as infections and pain) of the lesion; Preventive application should be made also in patients with comorbidities typically involved in healing delays such as diabetes, malnutrition, blood flow alterations and reduced oxygenation, etc. even if many studies show contrasting results.

The most critical issues about PRP are:



- 1) The variety of preparation methods (concentrations and centrifugation) and platelet activation techniques;
- 2) The choice of autologous plasma against homologous or allogeneic: the choice to use autologous plasma is strongly recommended in order to avoid problem of contagious disease and immune response;
- 3) The presence of leucocytes: is hasn't been proved if they add an immune response;
- 4) The timing and cost of preparation;
- 5) The long-term safety assessment;

Therefore, it is necessary to continue the research, the healing process depends not only on growth factors but also on appropriate wound care, infection control and nutrition (global takeover) (11).

Our results encourage PRP Gel as a safe, easy-to-handle, low-cost and risk-free alternative in wound healing for patients with acute trauma wound; This may be of particular relevance in hospitals which do not have an onsite team of plastic surgeons and patients are treated exclusively under the care of orthopedic surgeons.

## References

1. Knezevic NN, Candido KD, Desai R, Kaye AD. Is Platelet-Rich Plasma a Future Therapy in Pain Management? *Med Clin North Am* 2016; 100: 199-217.
2. Yu W, Wang J, Yin J. Platelet-rich plasma: a promising product for treatment of peripheral nerve regeneration after nerve injury. *Int J Neurosci* 2011; 121: 176-80.
3. Borriore P, Gianfrancesco AD, Pereira MT, Pigozzi F. Platelet-rich plasma in muscle healing. *Am J Phys Med Rehabil* 2010; 89: 854-61.
4. Pavlovic V, Ciric M, Jovanovic V, Stojanovic P. Platelet Rich Plasma: a short overview of certain bioactive components
5. Behm B, Babilas P, Landthaler M, Schreml S. Cytokines, chemokines and growth factors in wound healing. *JEADV* 2012; 26: 812-20.
6. Fr chet J-P, Martineau I, Gagnon G. Platelet-rich Plasmas: Growth Factor Content and Roles in Wound Healing. *J Dent Res* 2005; 84(5): 434-9.
7. Gano C, Tenewitz FE, Wilson RS, Moyles BG. The treatment of nonhealing wounds using autologous platelet-derived growth factors. *J Foot Ankle Surg* 1993; 32(3): 263-8.
8. Marlovits S, Mousavi M, Gabler C, et al. A new simplified technique for producing platelet-rich plasma: a short technical note. *Eur Spine J* 2004; (Suppl. 1): S102-106.
9. Mazzucco L, Medici D, Serra M, et al. The use of autologous platelet gel to treat difficult-to-heal wounds: a pilot study. *Transfusion* 2004; 44(7): 1013-8.
10. Wang H-L, Avila G. Platelet Rich Plasma: Myth or Reality? *Eur J Dent* 2007 Oct; 1(4): 192-4.
11. Kazakos K, Lyras DN, Verettas D, Tilkeridis K, Tryfonidis M. The use of autologous PRP gel as an aid in the management of acute trauma wounds, Injury. *Int J Care Injured* 2009; 40: 801-5.

Received: 24 October 2017

Accepted: 7 November 2017

Correspondence:

Alessio Pedrazzini

Orthopaedic Unit, Oglio Po Hospital

Via Staffolo 51 – 26041 Vicomosciano (CR), Italy

E-mail: alessio.pedrazzini@ospedale.cremona.it