

Surgical treatment of displaced acetabular fractures: report of 13 clinical cases

Massimo Pompili, Michele Arcangelo Verdano, Letizia Marenghi, T. Corsini, Francesco Ceccarelli

Orthopaedical Clinic. Department of Surgical Sciences, University of Parma, Parma Hospital, Parma, Italy

Abstract. *Background and aim of the work:* Displaced acetabular fractures are complex lesions which may cause severe consequences if not appropriately treated. The results are linked to the quality of the articular reduction. Anatomical reduction, through surgical treatment with rigid internal fixation, should be considered to obtain an early mobilization, reduce long term osteoarthritis evolution and make the acetabular cavity suitable to eventually receive a total hip prosthesis. The aim of this study is to evaluate functional and radiographic outcome of patients with displaced acetabular fractures surgically treated. *Methods:* Between 2005 and 2011, 29 displaced acetabular fractures were treated with open reduction and internal fixation. This study highlights our results in 13 patients with a mean follow-up of 29,5 months (range 5,5-66,3). Clinical evaluation was done according to the Harris hip score, while the radiological criteria were those of Kellgren-Lawrence. The associated injuries and complications were evaluated. *Results:* At the latest follow-up the radiological results, based on the Kellgren-Lawrence grading scale, showed 3 patients with a I grade of osteoarthritis, 5 with a II grade, 3 with a III grade and 2 with a IV grade. The average Harris hip score was 77 (range 37-100). Postoperative complications included avascular necrosis of the femoral head in 3 patients and heterotopic ossification in 2 patients. *Conclusions:* This study confirms that open reduction and internal fixation in displaced acetabular fractures represents the best treatment able to lead to a satisfactory functional outcome. Moreover, it posticipates long-term arthrosis and eventually makes easier the implant of total hip prosthesis. (www.actabiomedica.it)

Key words: acetabulum, fracture, reduction, internal fixation

Introduction

Displaced acetabular fractures are probably one of the most complex orthopaedic injury and still now represents a challenge for the surgeons. These fractures are relatively rare representing 3 cases/100.000 people per year (1, 2). Moreover, in polytraumatized patients, musculoskeletal, neurologic and soft tissues injuries can complicate evaluation and treatment. The anatomical complexity of the acetabulum and pelvis, the difficulty to define and classify the type of fracture, make the treatment decision more challenging.

Acetabular fractures are often the consequence of

a high-energy trauma. The three main mechanisms of injury were motor-vehicle accidents, falls from heights < 3 meters and pedestrians hit by a vehicle. Other mechanisms included sport incidents and crush injuries (1).

The decision between surgical or conservative treatment is often controversial. Many factors should be considered: the type of fracture, patient comorbidities, hospital facilities and professional skills of the surgeon.

Only after 1964, with Judet and Letournel the surgical treatment of displaced fractures of the acetabulum has been preferred over the conservative treat-

ment. These authors recognised that the principles applied to the treatment of displaced articular fractures (anatomical reduction, stable fixation and earlier mobilization) should also be applied to the acetabulum (3).

Open reduction and internal fixation is nowadays the gold standard for this type of fractures.

In a comparative study, the conservative treatment of displaced acetabular fractures showed worse results in comparison with the surgical treatment (good results in 30% in the conservative treated group versus 86% of good results of the surgical group) (4).

The advantages of surgical treatment includes: the visualization of the articular surfaces, better reduction of the fracture, better anatomical restoration of the acetabular surface, the possibility to remove loose fragments, the possibility to achieve stable fixation and a faster recovery of joint motion.

Clinical result after open reduction and internal fixation is related to many factors: patient's comorbidity and quality of the bone, intensity of the traumatic mechanism, the type of fracture, the injury of the acetabular or femoral head cartilage, the vascularization and the neurologic tissue. Two other related factors are the quality of articular reduction and the quality of internal fixation. The first one aims to achieve the congruency; the second one should be return the stability.

However, many studies confirms that post-traumatic osteoarthritis involves 30% of the patients, despite the purposes of the treatment are obtained (5-9).

Letournel and Judet recognized as negative factor for the outcome of the acetabular fractures, the failure of the acetabular surface reduction when the articular gap is more than 2 mm (10). They showed that the reduction's accuracy in acetabular fractures surgery was directly related to clinical outcome and that perfect reduction and stable fixation is the ultimate goal in any operative intervention (11).

Therefore, the surgical treatment aims to obtain an anatomical reduction of the articular surface, this allow an earlier mobilization of the hip (4), a lesser rate of osteoarthritis and make the acetabular cavity suitable for a secondary total hip prosthesis, if necessary.

The aim of this study is to evaluate functional and radiographic outcome of patients with displaced

acetabular fractures surgically treated in relation with the evolution of osteoarthritis.

Methods

Between August 2005 and June 2011, 29 displaced acetabular fractures were treated with open reduction and internal fixation.

Two patients died for external reasons, three could not be included in the study and eleven could not be traced. Therefore, 13 patients were available for follow-up.

Exclusion criteria for this study were: presence of pathological fractures, pseudo-arthritis, story of tumor or metastasis, follow-up inferior to 5 months and patient with comorbidity reducing the functional recovery.

After an initial stabilization of the general conditions, the preoperative assessment included detailed physical examination and plain radiograph of the pelvis in anteroposterior, iliac and obturator views. Pelvis computed tomography (CT) scanning and 3D-CT was performed in every patient for a better description of the fracture, pre-operative study and surgical indication.

Out of the 13 patients, were 11 men and 2 women. The average age was 48 years (range 26-74 years).

Eight cases were injuries due to traffic accidents, two cases followed a falling from high, one case after a sport accident with bicycle, one fall accidentally during a walk and one was a job injury.

Each fracture was classified, on the basis of a preoperative radiography, as per Judet and Letournel classification. Five fractures were classified as simple and the remaining eight were classified as complex.

The indications for surgical fixation, in patients with suitable general medical conditions, included all the displaced fractures with an incongruent articular steps of more than 2 mm crossing the acetabulum weight-bearing dome. The fracture in this area may induce increased pressure on the joint cartilage and lead to osteoarthritis (11).

In seven fractures, only a single approach was used (1 Anterior Iliioinguinal and 6 Posterior Kocker-

Lagenbach approach). Six cases required a combined anterior and posterior approach.

The mean time between the trauma and surgical treatment day was 9 days (range 1-39).

All patients were under general anesthesia. In case of upper or lower limbs fractures, they were fixed before the acetabular surgery.

In 5 fractures, only the posterior Kocher-Langenbeck approach was used. The patient was placed in the prone position with a modically extension of the hip and a 90° flexed knee to reduce the sciatic nerve injury.

In 2 cases, patients were placed in the supine position, with extended hip and knee, and the surgical approach was the anterior ileo-inguinal one.

In the remaining 6 patients, a combined anterior and posterior approach was used.

The surgical treatment aims to obtain an anatomical reduction of the articular surface and a gap inferior of 2 mm, with interfragmentary screws or a combination of plates and screws to obtain a rigid internal fixation on displaced acetabular fragments.

Fractures with a residual gap of more than 2 mm were considered not satisfactory.

After the surgical treatment, an anteroposterior radiograph was performed to evaluate the reduction accuracy of the fracture and the right position of the screws and plates.

First post-operative day treatment started with an early passive hip mobilization with a progressive flexion. For the first 8 weeks, patients walked with partial weight bearing. After 3 months, progressive weight bearing was permitted.

All the recruited patients were clinically and radiologically assessed with a follow-up of 2 weeks, 1 month, 2 months, 3 months, 4 months and 1 year after the surgical treatment. To evaluate the clinical aspect the Harris hip score was used. Total score was divided in poor (<70), fair (71-80), good (81-90), excellent (91-100).

The osteoarthritis changes were evaluated through the Kellgren-Lawrence grading scale (Table 1). The post-operative radiographs were important in order to evaluate the early articular congruency and the radiographic evolution: post-traumatic arthritis of the hip often need a total prosthesis.

Table 1. Radiographic criteria of degenerative changes based on Kellgren Lawrence Grading Scale

Grade 1	Doubtful narrowing of joint space Possible osteophytic lipping
Grade 2	Definite osteophytes Definite narrowing of joint space
Grade 3	Moderate multiple osteophytes Definite narrowing of joints space Some sclerosis Possible deformity of bone contour
Grade 4	Large osteophytes Marked narrowing of joint space Severe sclerosis Definite deformity of bone contour

Results

According to Judet and Letournel classification 5 fractures were classified as simple (1 anterior column fracture, 3 posterior wall fractures, 1 transverse fracture) and the remaining 8 as complex fractures (6 both columns fractures, 2 posterior column with posterior wall fractures) (Table 2).

Six patients were assessed based on the Harris hip score as excellent, 2 good and 5 poor. At last follow-up, the mean Harris hip score results were 77 (range 37-100).

Every Harris hip score result was related to the type of fracture (Table 3) and the age of the patient (Table 4).

At the latest follow-up the radiological results, based on the Kellgren-Lawrence grading scale, showed 3 patients with a I grade of osteoarthritis, 5 with a II grade, 3 with a III grade and 2 with a IV grade.

Table 2. Type of fractures classified according to Judet and Letournel

Type of fracture	Nr	%
Simple fractures (5)		
Posterior wall	3	23
Anterior column	1	8
Transverse	1	8
Complex fractures (8)		
Both columns	6	46
Posterior wall with posterior columns	2	12

Table 3. Relation between the final Harris hip score and the type of fracture

Type of fracture	Excellent Nr (%)	Good Nr (%)	Fair Nr (%)	Poor Nr (%)
Posterior wall	2 (15)	0	0	1 (7)
Anterior column	0	1 (7)	0	0
Transverse	1 (7)	0	0	0
Both columns	2 (15)	1 (7)	0	3 (23)
Posterior wall with posterior column	1 (7)	0	0	1 (7)

Table 4. Relation between the final Harris hip score, the mean age and number of patients

Harris hip score	Grade	Number of patients	%	Mean age (years)
<70	Poor	5	37	41
71-80	Fair	0	0	
81-90	Good	2	15	50
91-100	Excellent	6	46	51

Also in this case, every Kellgren-Lawrence grading scale result was related to the type of fracture (table 3).

At the time of presentation, 5 patients shown a sciatic nerve injury, 2 posterior luxations of the hip, 3 patients a retroperitoneal hematoma. For 2 patients an embolization of injured blood vessel was necessary. Six patients had an associated upper or lower limb fracture.

Main postoperative complications included avascular necrosis of the femoral head in three patients (23%) and heterotopic ossification in two patients (15%). Two patients required a total hip replacement.

Discussion

Surgical treatment with open reduction and internal fixation represents the best treatment leading to an acetabular surface anatomical reduction (5, 12-15).

The surgical treatment aims to achieve a satisfactory function and range of movement of the hip without pain (12, 15).

The main complication is post-traumatic osteoarthritis. Other complications are avascular necrosis of the femoral head, acetabular bone loss, shor-

tening of the lower limb and heterotopic ossification.

In this study with 13 patients, 8 (62%) showed a good or excellent functional outcome at the Harris hip score while the result found in literature was a 76%. Furthermore, in our study, the frequency of "both columns" fractures is higher than in literature data (46% versus 8%) (16-18).

In literature the post-traumatic osteoarthritis is between 20-50% after an acetabular fracture (6, 7, 13, 22-24). After our data analysis, we found 5 patients (38%) with a III and IV grade of osteoarthritis according to Kellgren-Lawrence grading scale (Figs. 1 and 2).

The factors related to the development of osteoarthritis were the fracture pattern severity, a posterior hip luxation and intrarticular lesion of the hip head and the acetabular surface (6, 25).

The main complications we found during our follow-up were 3 avascular necrosis of the femoral head within one year. The frequency found in literature is between 3% and 10% (5,12) but in case of posterior displaced fractures the percentage increases (18), like in our study. These patients had 1 posterior wall fracture, 1 posterior wall with posterior column fracture and 1 both columns fracture.

The nervous lesion frequency in the acetabular fracture corresponds to 16% but increases to 40% if the fracture presented also a posterior luxation (14) and in the 2-6% of iatrogenic injury, especially when the combined anterior and posterior surgical approach was used. The sciatic nerve was the most involved (12, 14).

Five patients showed a post-traumatic sciatic nerve injury whereas no cases of iatrogenic lesion was found. At the last follow-up, these patients recovered the nerve function partially the nerve function. The

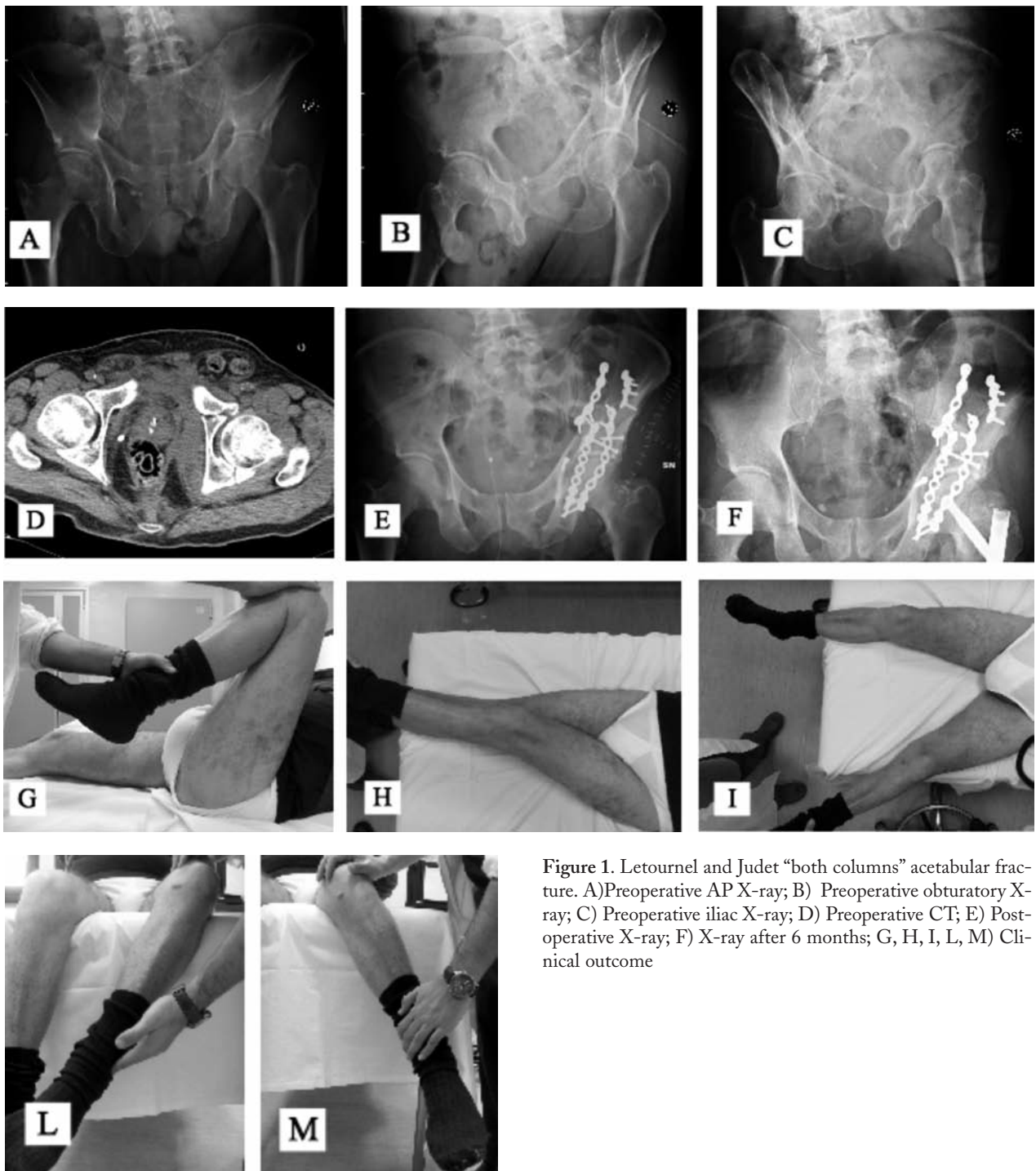


Figure 1. Letournel and Judet “both columns” acetabular fracture. A) Preoperative AP X-ray; B) Preoperative obturator X-ray; C) Preoperative iliac X-ray; D) Preoperative CT; E) Post-operative X-ray; F) X-ray after 6 months; G, H, I, L, M) Clinical outcome

suffering involved especially external sciatic popliteal nerve.

In our study, 2 patients developed heterotopic ossification and in one of these the surgical removal was necessary. In literature we found a 25,6% of inci-

dence after a surgical treatment in case of acetabular fracture. The risk factors for the development of heterotopic ossification are: extended surgical approach, high injury severity score, delayed reduction and fixation and head injury (14).

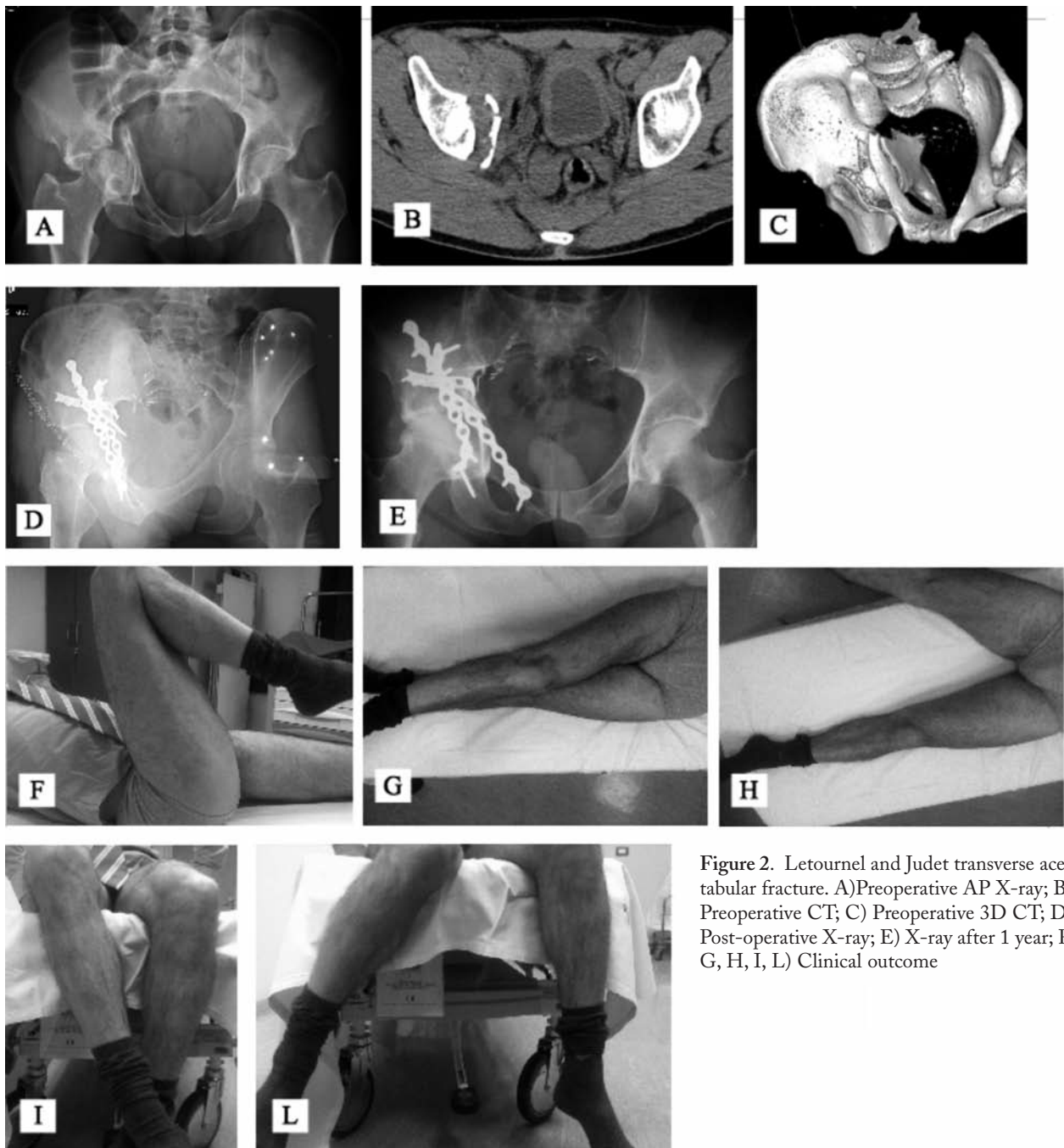


Figure 2. Letournel and Judet transverse acetabular fracture. A) Preoperative AP X-ray; B) Preoperative CT; C) Preoperative 3D CT; D) Post-operative X-ray; E) X-ray after 1 year; F, G, H, I, L) Clinical outcome

In conclusion, in comparison with the results shown in literature after conservative treatment, we can assert that in every displaced acetabular fracture, stated the low rate of iatrogenic complication observed, the surgical treatment with open reduction and

internal fixation allows a satisfying functional outcome, an earlier mobilization with a faster recovery and lower rate of osteoarthritis in the long term.

Moreover, it makes suitable the acetabular cavity for a secondary total hip prosthesis, if necessary.

References

1. Laird A, Keating JF. Acetabular fractures. A 16-years prospective epidemiological study. *JBJS* 2005.
2. Ochs BG, Marintschev I, Hoyer H, et al. Changes in the treatment of acetabular fractures over 15 years: analysis of 1266 cases treated by the German Pelvic Multicenter Study Group(DAO/DGU). *Injury* 2010; 41: 839-51.
3. Prevezas N. Evolution of pelvic and acetabular surgery from ancient to modern times. *Injury* 2007; 38: 397-409.
4. Kebaish AS, Roy A, Rennie W. Displaced acetabular fractures: long-term follow-up. *J Trauma* 1991; 31: 1539-42.
5. Matta JM. Fractures of the acetabulum. Accuracy of reduction and clinical results in patients managed operatively within three weeks after the injury. *J Bone Joint Surg Am* 1996; 78 (11): 1632-45.
6. Letournel E. Acetabulum fractures: classification and management. *Clin Orthop* 1980; 151: 81-106.
7. Mayo KA. Open reduction and internal fixation of fractures of the acetabulum. Results in 163 fractures. *Clin Orthop* 1994; 305 : 31-7.
8. Pennal GF, Davidson J, Garside H, Plewes J. Results of treatment of acetabular fractures. *Clin Orthop* 1980; 151: 115-23.
9. Ragnarsson B, Mjoberg B. Arthrosis after surgically treated acetabular fractures. A retrospective study of 60 cases. *Acta Orthop Scand* 1992; 63 (5): 511-4.
10. Letournel E, Judet R. Fracture of the acetabulum. Berlin; Springer; 1992.
11. Øvre S, Madsen JE, Røise O. Acetabular fracture displacement, roof arc angles and 2 years outcome. *Injury Int J Care Injured* 2008; 39: 922-31
12. Letournel E. Fractures of the Acetabulum. 2nd ed. New York. Springer-Verlag;1993
13. Matta JM, Merritt PO. Displaced acetabular fractures. *Clin Orthop* 1988; 230: 83-97.
14. Giannoudis PV, Grotz MR, Papakostidis C, Dinopoulos H. Operative treatment of displaced fractures of the acetabulum. A meta-analysis. *J Bone Joint Surg [Br]* 2005; 87 (1): 2-9.
15. Moed BR, Maxey JW. The effect of indomethacin on hetero- topic ossification following acetabular fracture surgery. *J Orthop Trauma* 1993; 7: 33-8.
16. Deo SD, Tavares SP, Pandey RK, et al. Operative management of acetabular fractures in Oxford. *Injury* 2001; 32 (7): 581-6.
17. Chiu F-Y, Chen C-M, Lo W-H. Surgical treatment of displaced acetabular fractures: 72 cases followed for 10 (6-14) years. *Injury* 2000; 31 (3): 181-5.
18. Petsatodis G, Antonarakos P, Chalidis B, Papadopoulos P, Christoforidis J, Pournaras J. Surgically treated acetabular fractures via a single posterior approach with a follow-up of 2-10 years. *Injury* 2007; 38: 334-43.
19. Matta JM, D.K. Mehne DK, Roffi R. Fractures of the acetabulum. Early results of a prospective study. *Clin Orthop* 1986; 205: 241-50.
20. Olson SA, Bay BK, Chapman MV, Sharkey NA. Biomechanical consequences of fracture and repair of the posterior wall of the acetabulum. *J Bone Joint Surg Am* 1995; 77 (8): 1184-92.
21. Vrahas MS, Widding KK, Thomas KA. The effects of simulated transverse, anterior column, and posterior column fractures of the acetabulum on the stability of the hip joint. *J Bone Joint Surg Am* 1999; 81 (7): 966-74.
22. Johnson EE, Matta JM, Mast JW, Letournel E. Delayed reconstruction of acetabular fractures 21-120 days following injury. *Clin Orthop* 1994; 305: 20-30.
23. Murphy D, Kaliszer M, Rice J, McElwain JP. Outcome after acetabular fracture. Prognostic factors and their interrelationships. *Injury* 2003; 34: 512-7.
24. Wright R, Barrett K, Christie MJ, Johnson KD. Acetabular fractures: long term follow-up and internal fixation. *J Orthop Trauma* 1994; 8: 397-403.
25. Liebergall M, Mosheiff R, Low J, et al. Acetabular fractures: clinical outcome of surgical treatment. *Clin Orthop* 1999; 366: 205-16.
26. Murphy MM, Zuakowski D, Vrahas MS. The death of articular chondrocytes after intra-articular fractures in humans. *J Trauma* 2004; 56: 128-31.
27. Kumar A, Shah NA, Kershaw SA, Clayson AD. Operative management of acetabular fractures: a review of 73 fractures. *Injury* 2005; 36 (5): 605-12.

Accepted: 19th September 2012

Correspondence: Verdano Michele Arcangelo,
 Clinica Ortopedica,
 Dipartimento di Scienze chirurgiche
 Via Gramsci 14, Parma (Italy)
 Tel. +39 347 2915328
 Fax +39 0521 70
 E-mail: micheleverdano@hotmail.it