

C A S E R E P O R T

Ataxia caused by a single dose of dexketoprofen trometamol

Sema Avcı, Selim Genç, Macit Aydın, Fatih Büyükcım, Seda Özkan

Department of Emergency Medicine, Dışkapı Yıldırım Beyazıt Training and Research Hospital, Ankara, Turkey

Summary. Mushroom poisoning is an important reason of plant toxicity. Wild mushrooms that gathered from pastures and forests can be dangerous for human health. The clinical outcomes and symptoms of mushroom toxicity vary from mild gastrointestinal symptoms to acute multiple organ failure. Toxic effects to kidney and liver of amatoxin are common but cardiotoxic effects are unusual. In this case, we reported the cardiotoxic effect of amatoxin with the elevated troponin-I without any additional finding in electrocardiography, echocardiography and angiography

Key words: cardiac enzyme, mushroom, poisoning, toxicity, troponin

Introduction

Dexketoprofen trometamol is one of the non-steroid anti-inflammatory drugs (NSAID) used as analgesic (1). It is a water-soluble molecule and it is an active enantiomer of racemic ketoprofen (1). Peroral dexketoprofen has considerable analgesic potency and well-tolerated adverse effects in patients who suffer from acute and chronic pain (1). Dexketoprofen treatment can lead to various adverse effects like nausea, vomiting, gastrointestinal hemorrhage, acute kidney injury, headache, anxiety and dizziness (1). However, ataxia isn't reported as an adverse effect of dexketoprofen. Herein we reported ataxia as a side effect of dexketoprofen in 41-year-old-women.

Case report

A 41 year-old- woman admitted to emergency department with speech disorder and vertigo for two hours. The patient had taken 25 mg of dexketoprofen trometamol for headache treatment approximately three hours ago. The patient's vital signs were as follows; blood pressure: 110/60 mmHg, body tempera-

ture: 37.1°C, hearth rate:75 beats/min. On physical examination, the patient was oriented, alert and conscious. Neurological examination was normal except ataxia and dysarthria. She has no previous chronic diseases. Laboratory results were as follows; glucose:102 mg/dL, creatinine:0.61 mg/dl, alanine aminotransferase (ALT): 8 U/L, aspartate aminotransferase (AST): 12 U/L, calcium:9.7 mg/dL, sodium:143 mEq/L, potassium:4.5 mEq/L, white blood cell: 6.1×10^3 /mL, hemoglobin:13.7 gr/dL, hematocrit:41.3%, platelet: 277×10^3 /ml, pH:7.391, pCO₂:40 mmHg, pO₂:39.5 mmHg, HCO₃:23.7 mmol/L. There was no pathology in electrocardiogram (ECG). Brain computed tomography and diffusion weighted magnetic resonance imaging were normal (Figure 1). The patient was discharged about four hours later due to regression of clinical symptoms.

Discussion

NSAIDs are commonly used for analgesic, anti-inflammatory and antipyretic effects (2). NSAIDs inhibit cyclo-oxygenase enzyme and suppress the prostaglandin synthesis reaction (2). Dexketoprofen which

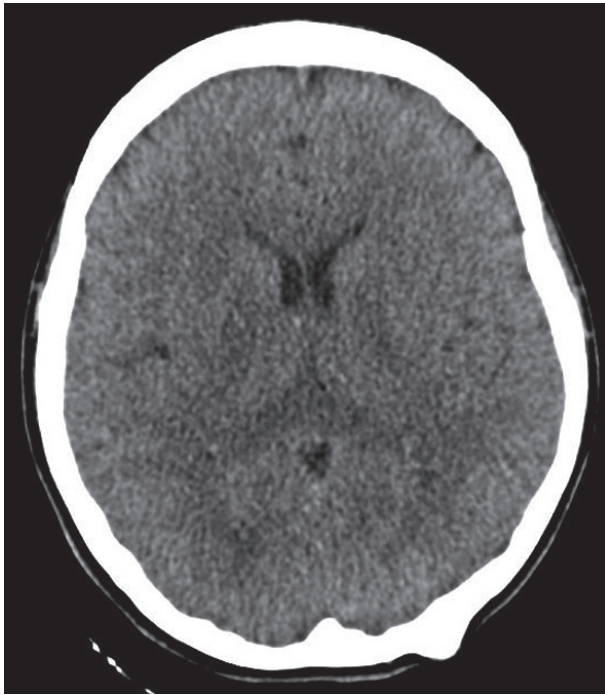


Figure 1. Computed tomography of the patient

is the derivation of arylpropionic acid is one of the NSAIDs which inhibits COX-1 and COX-2 receptors (2). Dexketoprofen trometamol that is the S(+) enantiomere of ketoprofen has minor side effects compared to racemic conjugate (2). NSAIDs adhere induced cyclo-oxygenase receptors that take part in dorsal horn of the spinal cord (3).

NSAIDs are safe but they can cause adverse effects even at therapeutic doses (3). The adverse effects of at therapeutic doses are renal failure, hyperkalemia, platelet dysfunction, bone marrow suppression, gastrointestinal hemorrhage, perforation, dyspepsia, hepatic injury, elevated serum transaminases, increased risk of myocardial infarction, pulmonary edema, bronchospasm, photosensitivity reactions, slow uterine contractions and neurological side effects like headache, dizziness aseptic meningitis, altered mental status and acute psychosis (3). Sav et al. reported a single-dose-dexketoprofen induced acute kidney injury due to

massive rhabdomyolysis (1). Zabala et al. reported neutropenia, thrombocytopenia and hepatic injury associated with dexketoprofen trometamol therapy in 2008 from Spain (4). Galindo et al. reported photocontact dermatitis and contact urticaria due to dexketoprofen trometamol and ketoprofen (5).

In medical literature, various adverse effects of dexketoprofen trometamol can be seen but there is no sample case of ataxia due to dexketoprofen. We aimed to share this adverse effect of dexketoprofen trometamol in peroral use.

References

1. Sav T, Unal A, Erden A, Gunal AI. Single-dose-dexketoprofen-induced acute kidney injury due to massive rhabdomyolysis. *Int Urol Nephrol.* 2012;44(5):1581-3.
2. Ekmekci P, Kazak Bengisun Z, Kazbek BK, Ozis SE, Tastan H, Suer AH. The efficacy of adding dexketoprofen trometamol to tramadol with patient controlled analgesia technique in post-laparoscopic cholecystectomy pain treatment. *Agri.* 2012;24(2):63-8.
3. Rella JG, Carter WA. Nonsteroidal Anti-Inflammatory Drugs. In: Tintinalli JE, editor. *Tintinalli's Emergency Medicine A Comprehensive Study Guide.* 7th ed. China: The McGraw-Hill Companies; 2011. p. 1254-5.
4. Zabala S, Calpe MJ, Perez G, Lerin FJ, Mouronval L. Neutropenia, thrombocytopenia and hepatic injury associated with dexketoprofen trometamol therapy in a previously healthy 35-year-old woman. *J Clin Pharm Ther.* 2008;33(1):79-81.
5. Cuerda Galindo E, Goday Bujan JJ, del Pozo Losada J, Garcia Silva J, Pena Penabad C, Fonseca E. Photocontact dermatitis due to dexketoprofen. *Contact Dermatitis.* 2003;48(5):283-4.

Received: 23 February 2014

Accepted: 17 March 2014

Correspondance:

Sema Avcı, MD

Department of Emergency Medicine,

Dışkapı Yıldırım Beyazıt Training and Research Hospital,
Ankara, Turkey

Phone: +90 312 596 2000

Fax: +90 312 318 6690

E-mail: semaakhan@hotmail.com