

Early-stage radiological critical analysis of unsuccessful cases following a four-part fracture osteosynthesis of the proximal humerus: focus on the “P” sign

Georgios Touloupakis, Wilfried Stuflesser, Fabrizio Ferrara, Alessio Maione, Guido Antonini, Cornelio Crippa

Department of Orthopedics and Traumatology, San Carlo Borromeo Hospital, Milan, Italy

Summary. Radiological evaluation of complex intra-articular fractures of the proximal humerus is still challenging. Here, we describe the post-operative “P” sign as a reproducible radiographical mark of a varus reduction, performed by assembling a head-shaft angulation of less than 130 degrees. Our retrospective study was conducted in a group of subjects who previously suffered from proximal humerus four-part fractures. We evaluated the post-operative evolution of specific radiographical parameters that are of crucial prognostic significance: Cervix-diaphysis angle (HHSA), quality level of the orthopaedic reduction (insufficient, sufficient and good) based on a radiological generalized subjective overview, presence of calcar screws through the Philos plate. The final cohort included a group of 39 patients of 70.76 ± 8.3 years of age and an average follow-up of 7.2 months. The post-operative mean HHSA was 131.5 ± 9.4 . Interestingly, a positive correlation was detected between presence of the radiographical “P” sign in the post-operative period and the number of surgical complications coming up in the post-operative period (OR: 3.68 - I.C. 95%: 0.7984255-19.2532430), although not statistically significant. In our study, the high number of complications corresponds to literature database. Presence of the “P” sign could be a useful tool for assessing the quality of reduction during intra and post-operative radiological evaluation. We underline the importance of the “P” sign as a “quality of reduction” factor and strongly recommend its intra-operative monitoring as an additional tool together with a standard subjective evaluation of the reduction.(www.actabiomedica.it)

Key words: “P” sign; Four-part proximal humeral fractures; Surgical complications

Introduction

Radiological evaluation of complex intra-articular fractures of the proximal humerus is still challenging. The “sunset” sign typically seen in an anteroposterior X-ray view is a reliable and consistent indicator of four-part fractures of the proximal humerus (1).

Four-part fracture osteosynthesis of the proximal humerus are often complicated with screw perforations, humeral head necrosis and secondary displacement. A relatively high number of post-operative

complications have indeed been reported after plate-osteosynthesis and despite an apparently acceptable radiological exam result (2, 3). Numerous studies were conducted trying to address this issue by identifying putative common factors that could possibly be responsible for the generation of the aforementioned complications.

Here, we describe the post-operative “P” sign as a reproducible radiographical mark of a varus reduction, performed by assembling a head-shaft angulation of less than 130 degrees. The radiological aspect of the

proximal humerus in such cases resembles to the “P” letter.

We hypothesize that this radiological sign in the anteroposterior X-ray view of the shoulder, despite otherwise good radiological aspect, can possibly predict secondary displacement of the fracture in the follow-up period. The aim of this retrospective study was to examine unsuccessful cases associated with implant-related complications, as well as to evaluate the presence of the “P” sign in the post-operative period, following surgery of specific types of fractures and in correlation with precise osteosynthesis parameters.

Materials and methods

Our retrospective study was conducted in a group of subjects who previously suffered from proximal humerus four-part fractures. All patients had been operated in our surgical unit during a 4-year period from January 2011 to July 2015.

The patients met the following inclusion criteria: (1) patients > 50 years old, (2) presence of the “sunset sign” as a reliable indicator of a four-fragment fracture, (3) application of a 3-hole PHILOS-type plate-osteosynthesis (Synthes, Solothurn, Switzerland).

The exclusion criteria included: (1) presence of simultaneous fracture in the ipsilateral humeral diaphysis or in other body parts, (2) severe comorbidity (ASA \geq 4), (3) open fractures, (4) post-operative follow-up shorter than 3 months and (5) graft insertion (void fillers).

The X-ray images of all eligible subjects were obtained from the picture archiving and communication system (PACS) of our institute and examined in at least 2 standard projections (anteroposterior projection on neutral rotation and anteroposterior oblique projection of the shoulder joint).

We evaluated the post-operative evolution of specific radiographical parameters that are of crucial prognostic significance: Cervix-diaphysis angle (HHSA), quality level of the orthopaedic reduction (insufficient, sufficient and good) based on a radiological generalized subjective overview, presence of calcar screws through the Philos plate.

The radiographical “P” sign was defined as an indicator of reduced fractures with an HHSA being

less than 130°. Post-operative complications considered were the following: humeral head necrosis, loss of reduction, hardware mobilization, and intraarticular protrusion of the screws. Statistical analysis was performed using free R software (The R Foundation for Statistical Computing, Vienna, Austria).

Results

A total number of 81 patients met the inclusion criteria; among them, 42 subjects were eliminated from the study due to the presence of at least one exclusion criteria (an incomplete follow up, was present in most of the cases).

The final cohort included a group of 39 patients of 70.76 ± 8.3 years of age and an average follow-up of 7.2 months. The post-operative mean HHSA was

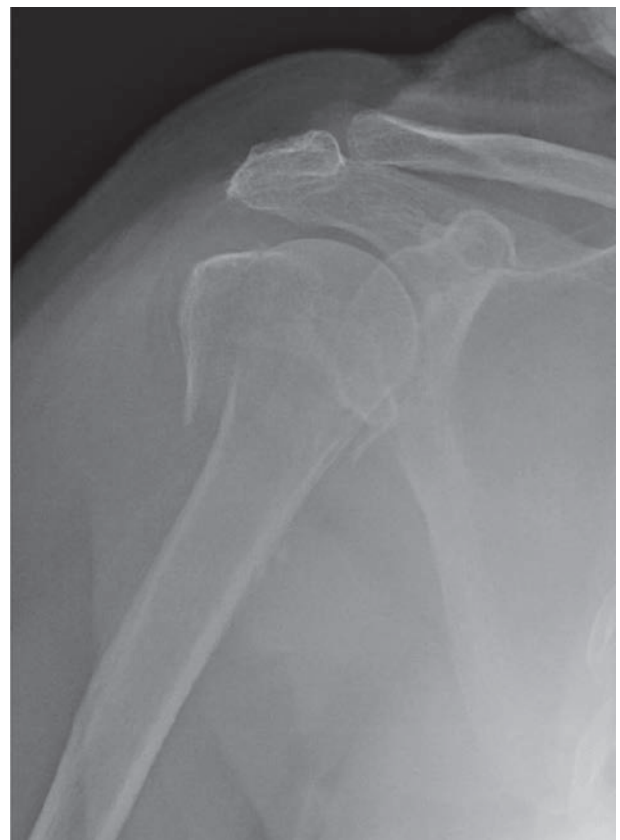

Figure 1. 4 Radiographs of a 75-year-old woman with a four-part fracture osteosynthesis of the proximal humerus: the “sunset” sign is visible in the anteroposterior view

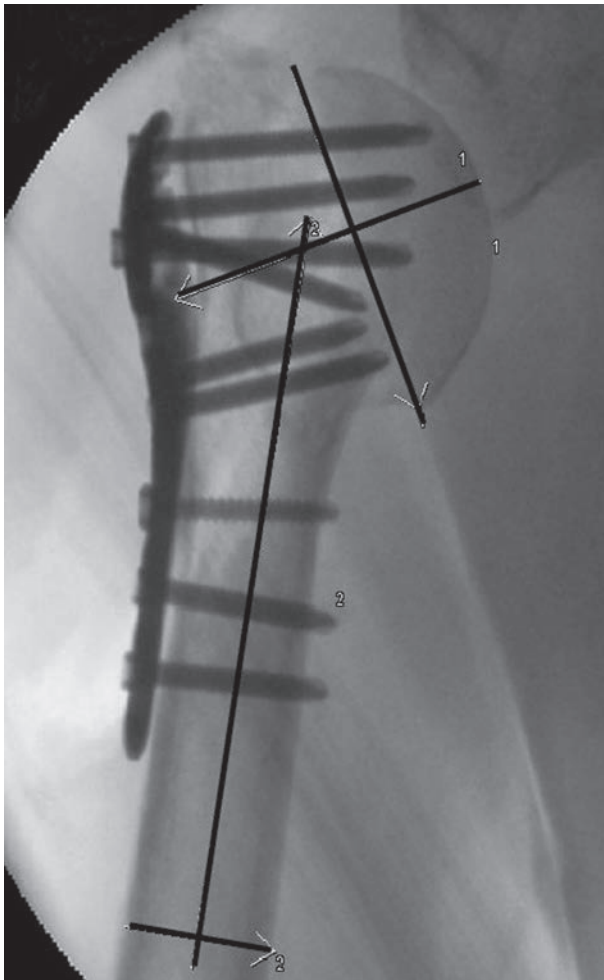

Figure 2. Postoperative radiograph demonstrated fracture reduction in varus ($119,61^\circ$) with the described “P sign”

131.5 ± 9.4 . In 23 patients, post-operative reduction was tested excellent (58.97%), while it was found either good or insufficient in 8 cases per each of these two categories (20.51%). Calcar screws were placed in a total of 27 patients (69.23%). The “P” sign was confirmed positive (presence) in 16 patients.

Among patients tested positive for the “P” sign, post-operative reduction was considered good in 43.7% of cases, sufficient in 18.7% and insufficient in 37.5% of them. Among the remaining patients that were found negative for the “P” sign (absence), 69.5% of them presented with good reduction, 2.7% with sufficient and 8.6% were found to have insufficient post-operative reduction. Statistical analysis with contingency table revealed no significant differences in terms

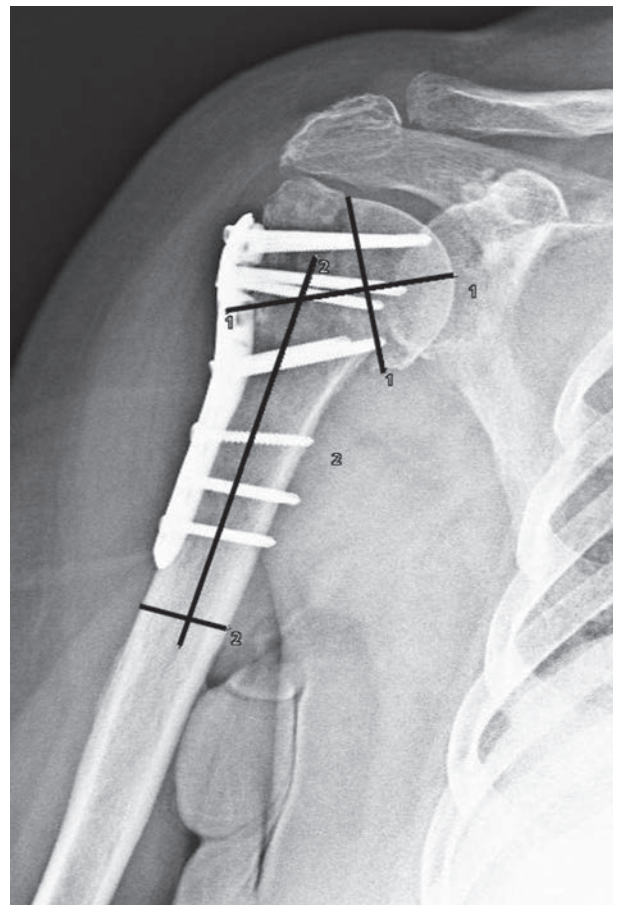


Figure 3. Radiograph at 1 month of follow-up showing progressive loss of reduction of the head ($117,56^\circ$)

of quality of reduction between the two major groups, meaning between patients with presence and with absence of the “P” sign.

A total number of 14 patients (35.9% of cases) went through post-operative complications during follow-up within a mean time of 10.7 months. Statistical analysis showed no positive correlation between the overall quality of the post-operative reduction and the number of unsuccessful cases, as well as between patients treated by osteosynthesis with and without calcar screws through the plate. Interestingly, a positive correlation was detected between presence of the radiographical “P” sign in the post-operative period and the number of surgical complications coming up in the post-operative period (OR: 3.68 - I.C. 95%: 0.7984255-19.2532430), although not statistically significant. Nevertheless, the average HHSA of the pa-

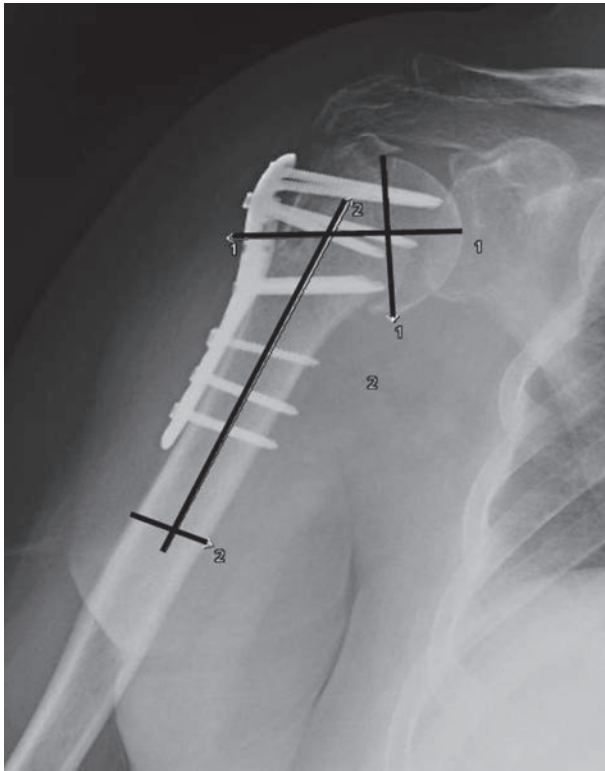


Figure 4. Radiograph at 3 months of follow-up (HHSA 115,49°) showing further loss of reduction.

tients that were basically considered unsuccessful cases was found to be 127,69 degrees while it was found significantly higher, equal to 133,91 degrees, ($p=0,03$) in patients with satisfactory radiographical follow up. No statistically significant differences were detected in multivariate data analysis, likely due to low number of patients in the sampling groups.

Discussion

There is no universal consensus on the treatment of four-part proximal humerus fractures and conservative non-surgical approaches typically lead to unsuccessful union, often complicated with shoulder stiffness and ultimately associated with poor functional results (4, 5). CT scan with 3d reconstruction provides detailed information about the type of the lesion, but it has been demonstrated that just the presence of the “sunset” sign in pre-operative X-ray, as a simple radiological sign, can by itself highlight the severity of the fracture.

Despite the several complications that often present with these types of fractures, the importance of radiological evaluation of the osteosynthesis during the peri-operative procedure and in the post-operative period has not been well investigated. Osteonecrosis of the proximal humerus is well defined radiologically as a late complication; nevertheless, the morphologic changes that occur in the early post-operative period after plate-osteosynthesis of 4 part fractures of proximal humerus are not always captured in the short and medium term radiological controls (6). Furthermore, there are not precise prognostic factors universally accepted, that can ultimately lead to an optimal surgical technique. Varus migration of the humeral head after four-part fractures is indicative of secondary displacement of the fracture, which primarily depends on inadequate reduction and fixation, and sometimes represents an early sign of osteonecrosis. In our opinion, restoring an optimal head-shaft angle is of crucial importance for a successful treatment, as, missing an optimal head-shaft angle could lead to early failure, despite an otherwise good reduction.

The general recommendation for plate-osteosynthesis in complex proximal humerus fractures is still a topic of debate; arthroplasty is still remaining the most preferable option for such fractures by many surgeons, despite often poor clinical outcomes in terms of range of motion caused by such procedures (7). However, it has been demonstrated that osteosynthesis, apart from being less expensive, has overall more satisfactory clinical result, but a still noticeable risk of failure. More importantly, arthroplasty can always be a second-choice treatment in case a osteosynthesis by plate is not likely to be successful, while the opposite is not an option. In any case, four-fragment fractures of the proximal humerus are technically very challenging cases to treat, requiring long and complex orthopedic interventions. For that reason, it is important to operate using secure, precise and reproducible methods in order to obtain a safe and successful reduction, and so as to ensure the best clinical outcome that would definitively justify the preference for plate-osteosynthesis as the first-line treatment.

Many reported studies tried to address the issue trying to identify factors related to early failure (8). Good clinical practice requires intra-operative moni-

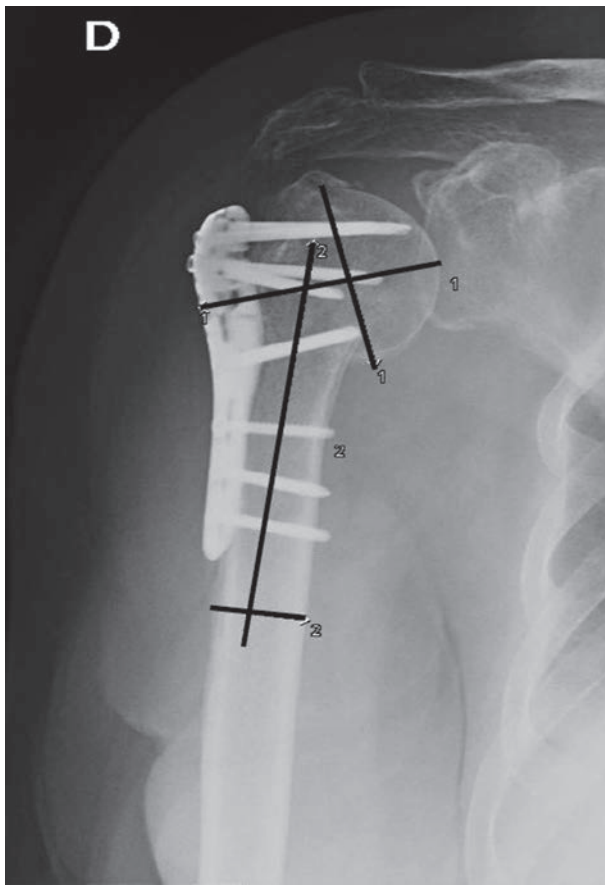


Figure 5. Radiograph at 6 months of follow-up (HHSA 111,43°) and at 9 months of follow-up (HHSA 111,40°) respectively highlights varus malalignment of the humeral head.

toring of the reduction so as to evaluate overall quality and evolution. While subjective interpretation of the X-ray images is usually sufficient in most cases in order to establish reliable prognosis, it is mandatory to confirm diagnostic hypothesis and establish best treatment options using objective criteria when such complicated cases arise. Some authors suggest that both a residual bone deformity and initial reconstruction within a range of 15 degrees in both views, as well as tuberosity displacement of 5mm or less are acceptable and should be the surgical goal of surgery by plate-osteosynthesis; our results also suggest that restoration of HSSA with values greater than 130 grades could be of great importance to prevent potential further displacement (9).

In our study, the high number of complications corresponds to literature database. Our results showed

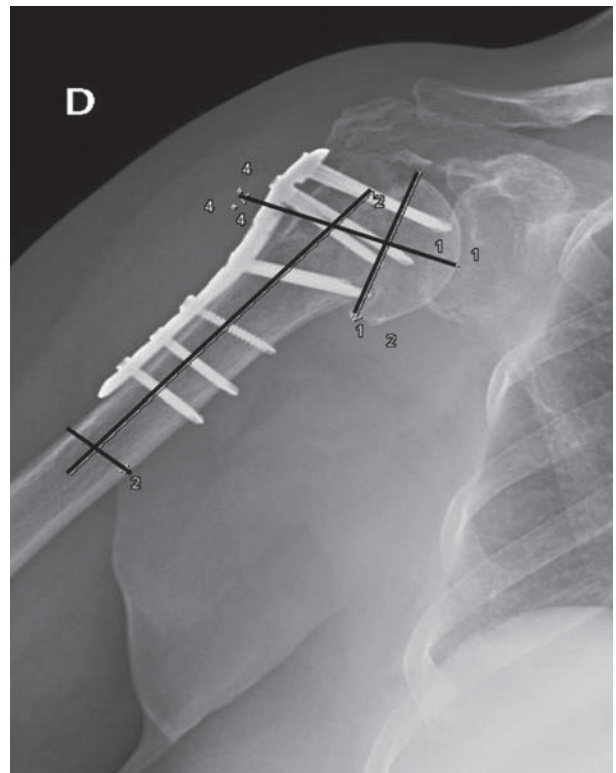


Figure 6. Radiograph at 6 months of follow-up (HHSA 111,43°) and at 9 months of follow-up (HHSA 111,40°) respectively highlights varus malalignment of the humeral head.

no positive correlation between presence of complications and overall quality of the reduction. It is striking that in 37.5% of the unsuccessful cases, post-operative reduction was considered good. On the other hand, and in the same group of patients, HHSA was found to be of lower degree compared to control subjects. Statistical analysis revealed trending but not significant differences between groups, likely due to low number of subjects to compare.

Presence of the “P” sign could be a useful tool for assessing the quality of reduction during intra and post-operative radiological evaluation. In this context, an important surgical aim of plate-osteosynthesis should be to obtain reduction with the appearance of the “P” sign, an outcome that would add objective value for considering a reduction successful or not. We reinforce this hypothesis, by reporting that in 43.7% of cases associated with the “P” sign, overall reduction was considered good. In conservative approaches, proximal humerus shape can change during fracture healing be-

cause of the absence of a fixation (10). Otherwise, in case of plate-osteosynthesis complicated with screws malposition or technical pitfalls like the underuse of calcar screws, an early mobilization can contribute to progressive fragment displacement (11, 12). In our cases, the position of calcar screws was not significant. Our hypothesis is that calcar screws increase solidity but also relative stiffness of the fracture fragments and the benefits of their application are associated only in cases of anatomic reduction when absolute stability is needed.

In this study the importance of bone void fillers was not evaluated (13). Passing from the “sunset” sign position to the anatomical valgus position, can often cause bone weakening especially in elderly patients. In our analysis, all the cases where bone augmentation was utilized have been excluded; it is possible that the number of complications was increased also for this reason. Moreover, our criteria for evaluating the success of the reduction are based on a radiological overview using a simple scale, without actually considering strict and determining parameters, but only strong indicators; nevertheless, this is the most diffused way of surgical evaluation during standard clinical practice worldwide. Furthermore, the small number of the subjects included in our sampling groups provided low statistical power of our retrospective analysis. Lastly, since the technical design of this study had to involve a multi-surgery approach, the operating surgeons did not share equal knowledge and expertise regarding shoulder implant surgery, and this fact may have posed significant limitations when we had to switch from plate-osteosynthesis to prosthesis in the case of non-reducible fractures.

In conclusion, we underline the importance of the “P” sign as a “quality of reduction” factor. We strongly recommend its intra-operative monitoring as an additional tool together with a standard subjective evaluation of the reduction. In many cases, it could be safer to proceed with prosthesis, when reduction with plate-osteosynthesis cannot be achieved together with the presence of the “P” sign. Such situations require careful decision making between osteosynthesis and humeral arthroplasty and readiness to change indication intra-operatively if necessary, in order to minimize radiological complications of inadequate fixation. The

presence of the “P” sign can also have a prognostic value; in these cases, mobilization protocols after surgery should be agreed in detail between the orthopedic surgeon and the physical therapist and they both need to adequately educate the patient to try to minimize further risks of complications.

References

1. Kachramanoglou C, Chidambaram R, Mok D. Four-part proximal humeral fractures: diagnosis with the ‘sunset’ sign on anteroposterior radiograph. *Ann R Coll Surg Engl* 2010 Oct; 92(7): 599-604
2. Spross C, Platz A, Rufibach K, Lattmann T, Forberger J, Dietrich M. The PHILOS plate for proximal humeral fractures--risk factors for complications at one year. *J Trauma Acute Care Surg* 2012 Mar; 72(3): 783-92.
3. Clavert P, Adam P, Bevort A, Bonnomet F, Kempf JF. Pitfalls and complications with locking plate for proximal humerus fracture. *J Shoulder Elbow Surg* 2010 Jun; 19(4): 489-94.
4. Maier D, Jaeger M, Izadpanah K, Strohm PC, Suedkamp NP. Proximal humeral fracture treatment in adults. *J Bone Joint Surg Am* 2014 Feb 5; 96(3): 251-61.
5. Gregory TM, Vandebussche E, Augereau B. Surgical treatment of three and four-part proximal humeral fractures. *Orthop Traumatol Surg Res* 2013 Feb; 99(1 Suppl): S197-207.
6. Campochiaro G, Rebuzzi M, Baudi P, Catani F. Complex proximal humerus fractures: Hertel’s criteria reliability to predict head necrosis. *Musculoskelet Surg.* 2015 Sep; 99 Suppl 1: S9-15.
7. Xie L, Ding F, Zhao Z, Chen Y, Xing D. Operative versus non-operative treatment in complex proximal humeral fractures: a meta-analysis of randomized controlled trials. *Springerplus* 2015 Nov 25; 4: 728.
8. Newman J, Kahn M, Gruson KI. Reducing Postoperative Fracture Displacement After Locked Plating of Proximal Humerus Fractures: Current Concepts. *Am J Orthop (Belle Mead NJ)* 2015 Jul; 44(7): 312-20.
9. Bahrs C, Kühle L, Blumenstock G, Stöckle U, Rolauffs B, Freude T. Which parameters affect medium- to long-term results after angular stable plate fixation for proximal humeral fractures? *J Shoulder Elbow Surg* 2015 May; 24(5): 727-32.
10. Foruria AM, Martí M, Sanchez-Sotelo J. Proximal humeral fractures treated conservatively settle during fracture healing. *J Orthop Trauma* 2015 Feb; 29(2): e24-30.
11. Bai L, Fu Z, An S, Zhang P, Zhang D, Jiang B. Effect of Calcar Screw Use in Surgical Neck Fractures of the Proximal Humerus With Unstable Medial Support: A Biomechanical Study. *J Orthop Trauma* 2014 Aug; 28(8): 452-7.
12. Osterhoff G, Ossendorf C, Wanner GA, Simmen HP, Wer-

- ner CM. The calcar screw in angular stable plate fixation of proximal humeral fractures - a case study. *J Orthop Surg Res* 2011 Sep 24; 6:50.
13. Katthagen JC, Schwarze M, Meyer-Kobbe J, Voigt C, Hurschler C, Lill H. Biomechanical effects of calcar screws and bone block augmentation on medial support in locked plating of proximal humeral fractures. *Clin Biomech (Bristol, Avon)* 2014 Aug; 29(7): 735-41.

Received: 18 March 2016

Accepted: 11 April 2016

Correspondance:

Georgios Touloupakis

Via Don Bartolomeo Grazioli 24 - 20162 Milano

Tel. (+39)3495106291

E-mail: yorgostoulou@gmail.com