

# Clinical approach in PIPj flexion contracture conservative treatment: our experience

*Silvio Tocco<sup>1</sup>, Alessio Pedrazzini<sup>2</sup>, Francesco Pogliacomì<sup>2</sup>*

<sup>1</sup> Centro Riabilitativo della Mano e Arto Superiore, Fornovo Taro (PR), Italy; <sup>2</sup> Orthopaedics and Traumatology Clinic, Department of Surgical Sciences, University of Parma, Italy

**Summary.** Proximal interphalangeal joint (PIPj) flexion contractures are a common clinical problem seen by hand therapists and orthopaedic surgeons after various types of injury to the finger. Conservative treatment is preferable over surgery but a variety of pre-fabricated and custom-made orthoses have been proposed in the literature. The aim of the present paper is to share our 15 year experience in treating PIPj flexion contractures using 2 different custom-fabricated orthoses and the exercise regimen used to preserve maximal PIPj passive and active extension obtained through the orthotic intervention. Synthetic serial casting and static-progressive splinting are in our opinion the best choices to treat even the most resilient PIPj flexion contractures as they both offer maximal Total-End-Range-Time (TERT) and minimize functional impediment of the hand while they are in use. Either approach offers advantages and set-backs that need to be discussed with the patient once his or her functional demands and ADL/leisure limitations have been identified. ([www.actabiomedica.it](http://www.actabiomedica.it))

**Key words:** finger, joint, interphalangeal, flexion, contracture

## Introduction

Proximal interphalangeal joint (PIPj) flexion contractures are a common clinical problem seen by hand therapists and orthopaedic surgeons after various types of injury to the finger (1). Joint dislocation or subluxation, synovitis or simply joint edema originating from a nearby injury to the hand are some of the causes of PIPj flexion contractures (1,2). After trauma, periarticular structures can shorten if a joint is unable to move through its full range for a prolonged period of time (3). Orthotic techniques to remodel shortened soft tissue structures are well described by Fess (4). Different prefabricated mobilizing orthoses, such as the LMB TB spring wire, reverse knuckle bender, Capener orthosis, Joint Jack, and Dynasplint are available in the market to treat PIPj flexion contractures (4). In addition to the variety of prefabricated orthoses, a variety of custom low-profile models (5,6) and casting approaches, such as serial casting and the casting

motion to mobilize stiffness technique (CMMS) can also be used to treat PIPj flexion contractures (3,7).

The aim of the present paper is to share our experience in treating PIPj flexion contractures using 2 different orthotic interventions or a combination of both. The exercise regimen used to preserve the gains once maximum passive PIPj extension has been obtained with the selected orthoses will also be presented.

## Orthosis selection - Our personal experience

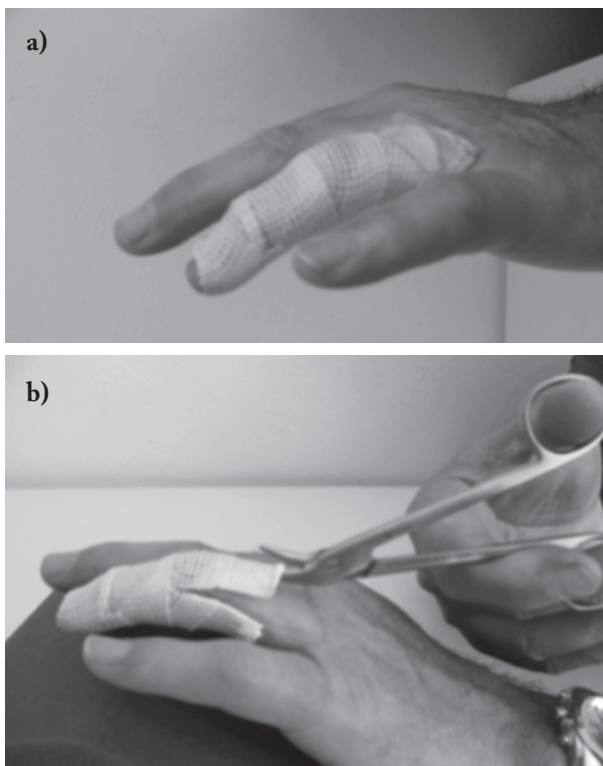
Recently, redirected motion and CMMS have been proposed to treat chronic stiffness of the hand (3). Although we use these approaches in cases of chronic stiffness of multiple joints of the hand and wrist, patients rarely accept this approach when a single joint of 1 or 2 fingers are involved.

A recent randomized clinical trial study has shown the benefits of alternating serial static and dynamic or-

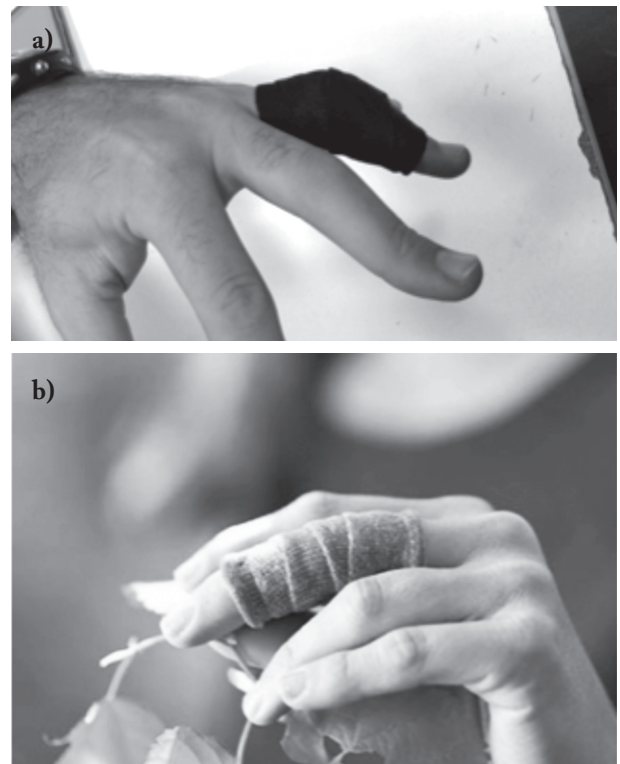
theses between night and day, respectively (8). However, because low-profile dynamic orthoses (p.e. Colditz's Spring-Wire) (2,7) require great caution and splinting experience to apply the right amount of mobilizing force through coil springs, this orthotic model may not be suited for all therapists. In addition, and regardless of orthotic management experience, joints suffering from severe stiffness benefit more from low-tension-prolonged-duration orthoses as proposed by Flower (9). Moreover, off-the-shelf commercial dynamic orthoses have been found to apply too much force on the PIPj (10), causing pain and reducing wearing time, which ultimately reduces Total-End-Range-Time (TERT) (11). Some high-profile custom-made dynamic orthosis may transmit adequate mobilizing forces through elastic bands such as in the Cantero-Télez and colleagues study (8) but function may greatly be compromised while wearing the device, potentially reducing patient compliance which would inevitably lengthen the treatment period in this cost-effectiveness era.

Plaster of Paris has been used centuries ago to immobilize joints (12) and revisited a few years ago by Brand (13) and Colditz (1) for its application in serially correcting joint deformities and more specifically PIPj. Although apparently effective in treating PIPj flexion contractures, this material is somewhat messy and lengthy in fabrication. In addition, if multiple fingers of the same hand must be treated simultaneously, the end result becomes bulky and cumbersome for the patient. Fortunately for hand therapists, innovative thinner, light and mess-free synthetic finger casting materials have been recently introduced on the rehabilitation market. Quickcast® finishing tape (Homecraft-Rolyan; Nottingham, UK) (Fig. 1) was the first of its line, later replaced by a latex-free version. Just recently Orficast® thermoplastic tape (Orfit Industries; Wijnegem, Belgium) (Fig. 2) has been introduced to the hand therapy community.

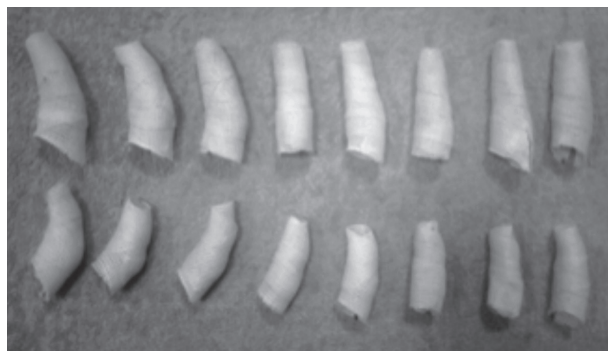As mentioned earlier, many approaches and orthotic models can be used to treat PIPj flexion con-



**Figure 1.** a) Quickcast® finishing tape. b) Cast scissors for safe removal



**Figure 2.** Different Orficast® thermoplastic tape (a and b)



**Figure 3.** Serial casting with Quickcast® finishing tape

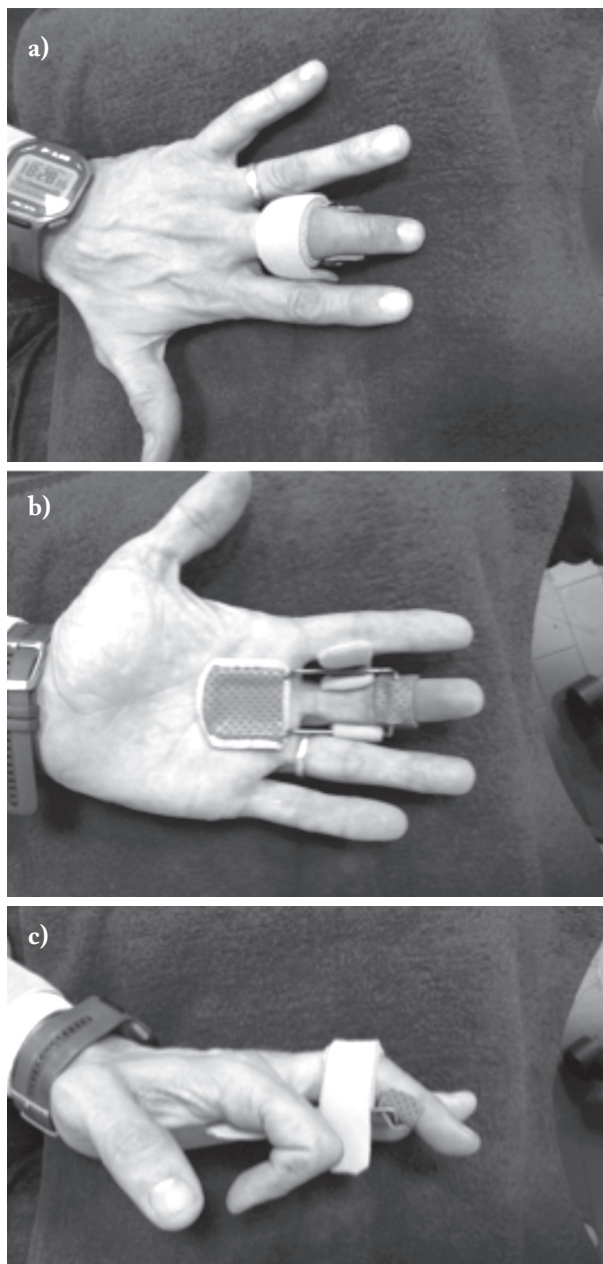
tractures but we prefer synthetic serial casting (Fig. 3) and the no-profile static-progressive orthosis (Fig. 4) (14) to provide maximum results in regards to time and passive range-of-motion (PROM) recovery.

### Synthetic serial casting vs. Static-progressive splinting

Quickcast® finishing tape (QC) holds similar properties to Plaster of Paris as described by Colditz (3) but with the advantage of being less bulky and can withstand water (i.e. enabling OP). The offset lies in cost of the material, which is slightly higher for QC, but its superior handling properties still makes it more cost-effective than traditional plaster cast. Also, QC can be reused if the finger position is not ideal once the material has hardened, reducing time and costs if it needs to be remolded a second or third time during a visit.

Serial casting with QC offers some advantages over the no-profile static-progressive splinting (SPS) model. The former can be used in extreme cases of PIPj flexion contractures whereas the SPS cannot be donned on fingers deformed by more than 70° of fixed flexion. Applying QC takes only a few seconds and 4 or 5 attempts to grasp the material's handling properties and correctly apply it on a deformed finger, whereas fabricating the no-profile SPS has a steeper learning curve and takes about 5-10 minutes to construct even for the experienced orthosis maker. Another advantage of QC over the no-profile SPS is that occupational performance (OP) is preserved in the former since only the

PIPj is included in the orthosis whereas the SPS also impedes metacarpal-phalangeal joint (MPj) motion because of its longer palmar lever-arm. The greatest benefit, however, in using QC over any other orthosis is that it rapidly reduces edema even in fibrotic joints due to its elastic property and allowing it to be applied in a stretched manner, similar to compressive cohesive



**Figure 4.** No-Profile PIPj Extension Static-Progressive Splint. a) Dorsal view. b) Lateral view. c) Volar view

bandage. The negative impact of joint edema is well known to hand therapists and surgeons alike and it is an important player in soft-tissue shortening and joint motion limitation (15). Therefore, reducing the diameter of the joint facilitates proper mechanics of the PIPj. Pain also subdues with QC, whereas SPS may cause greater pain if used too aggressively. Serial casting can be used to treat all 4 fingers of the same hand at once while only 1 or 2 non-adjacent fingers can be treated in a similar fashion with the SPS because of its greater width. Patients that are unable to cooperate or have physical or cognitive difficulties in handling assistive aids or orthoses benefit more from the serial casting approach than the no-profile SPS as the latter requires frequent and cautious home-based adjustments. Pressure distribution over the skin is more balanced with QC since it is circumferential whereas the SPS applies great pressure directly over the PIPj, which may cause pressure sores if the patient dons the orthosis too tight.

So the question comes to mind: “Why use the no-profile SPS if QC has so many more advantages?” Simply because the no-profile orthosis straightens PIPj flexion contractures in just a few days whereas serial casting may take several days or weeks to reach full extension or a plateau. In addition, follow-up visits are kept to a minimum with the no-profile SPS, whereas serial casting requires bi-weekly visits in the first few weeks of treatment. Today’s healthcare system, whether be in the public or private sector, demands highly cost-effective strategies. In cases of PIPj flexion contractures, SPS allow to reach this goal since it may be the most rapid way in improving passive extension. Hand corrective-orthoses should offer maximum function while used in order to maximize Total-End-Range-Time (TERT). High- and low-profile orthoses are bulky and may be socially undesirable to some patients. Dynamic orthoses, even if constructed with the right amount of tension, cannot be worn continuously for long periods of time since circulation may become an issue after several minutes of usage. Commercial models can be costly and not adaptable to everyone’s finger problem. The no-profile SPS requires some practice to how to make but almost no cost to fabricate since low-temperature thermoplastic (LTTP) scraps can be used to construct the distal cuff and proximal pad. Copper wire needed to construct the frame can be

purchased at any local hardware store at a reasonable price. This is why I personally consider the no-profile SPS, which was originally designed by Dominique Thomas (France) and later modified by Boccolari and Tocco, to maximize fitting and eliminate the need to adapt the line of pull of the central strap as the finger straightens. However, it is yet unknown which SPS model is more effective and only well-designed controlled randomized trials can answer this question in the future.

As for any other injury, careful physical examination and assessment of the PIPj will guide the therapist in choosing the most appropriate treatment approach. Joint integrity is assessed radiographically and with other diagnostic imaging techniques, if needed. If the joint is severely damaged and the proximal and middle phalanges are incongruent, any conservative treatment is bound to fail and surgery may be warranted. In addition, the finger pulley system needs to be preserved in order to maintain the extension (16) once the patient is free of orthoses and begins to flex the finger. In most cases, the patients will seek medical attention only weeks or months after the injury, when edema has filled the joint with fibroblastic tissue, leaving the joint thickened and surrounded by tight soft-tissue. In these cases, we recommend using serial casting to reduce the negative impact of chronic edema on joint mobility as described by Colditz (3). If joint pain is an issue SPS will be poorly tolerated, so serial casting is the preferred choice. Finally, if multiple adjacent fingers are affected, serial casting will allow simultaneous treatment, whereas the no-profile SPS can be used on alternate fingers because of its larger base of support in the palm of the hand. *Note: If a patient presents with 4 affected fingers, one can treat the II and IV fingers or the III and V fingers with the SPS and the other two with QC until full extension is gained in the fingers treated with SPS (often full extension obtained on the second visit 3–4 days later). The SPS can then be used on the other 2 fingers not yet fully extended to speed up the process of regaining full passive extension in all 4 fingers.*

During the first visit, both techniques should be explained to the patient by listing the advantages of each approach (Table 1). A client-center decision will thus be reached on the most suitable technique for that particular patient. Hence, the patient’s areas



**Table 1.** Comparison between Serial Casting and Static-Progressive Splinting (SPS)

	Serial Casting <sup>1</sup>	SPS <sup>2</sup>
Maximum PIPj flexion contracture angle	Can be used for all angles	Unable to use if >70°
TERT*	Moderate	Maximal
Speed of PIPj Extension Recovery	± 20 days	1-5 days
Learning Curve to Fabricate	4-5 attempts	5-10 attempts
Time expenditure to fabricate	± 30 seconds	± 5 minutes
Cost of Material	++	+
Edema reduction	+++++	None
Number of fingers that can be treated simultaneously	All 4	1 or 2 (non adjacent)
Functional impediment	Low (only PIPj limited)	Moderate (MPj** also limited by orthosis)
Patient compliance required to adjust orthosis	None	++++
Frequency of visits until maximum PIPj ext obtained	Every 3-5 days, up to 10 visits	1 or 2 visits overall
Pain reduction	Highly effective	May cause pain if patient unable to apply proper tension
Pressure sore risk	Low	High (over PIPj dorsal crease)
Skin maceration risk	None	Low

Legend:

1- Quickcast® finishing tape

2- Personal No-Profile Model (14)

\*Total End-Range Time

\*\* Metacarpal joint

of occupational performance, which may be affected with the lesser functional orthosis (SPS), need to be addressed. If a patient requires maximum use of the hand and cannot sacrifice even a few days of SPS because of work or leisure demands, serial casting is your best choice. It is also the best choice in patients with physical or cognitive impairments. Indeed, if skin problems are an issue (i.e. rheumatoid, cortisone users, incision over the PIPj, etc.), serial casting will distribute pressure over the entire finger better than the SPS because of its circumferential shape. If the patient cannot comprehend spoken or written instructions on how to tighten the SPS strap over the PIPj, it is recommended to use serial casting to eliminate any risks of mishandling the SPS and potentially create pressure sores of the dorsum of the joint. However, if a patient's residence is relatively far from our clinic and cannot comply with bi-weekly visits as required for serial casting, SPS is your choice as the overall number of visits

with this latter approach is low.

### Treatment process

Regardless of the choice of treatment, we follow 3 fundamental steps in order to restore maximal Total Active Range of Motion (TAM) for PIPj flexion contractures.

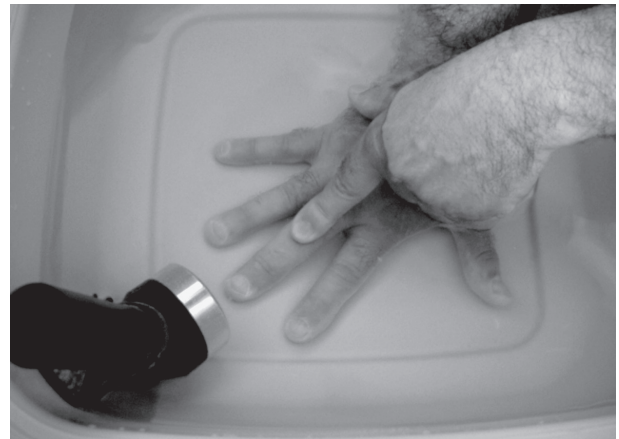#### *Step 1: contracture correction*

The first step is to recover full passive extension, regardless of any flexion difficulties. Some patients (and therapist!) may fear losing their partial or complete active PIPj flexion if the joint is left in full extension for a prolonged period of time. As therapists, we must reassure our patients by explaining that the joint's ligamentous complex (volar plate & collateral ligaments) is actually maintained taught in full extension. In addition, by leaving the DIPj free to flex while

immobilizing the PIPj in extension, the lateral bands migrate dorsally, which will later help maintain active PIPj extension and give more elasticity to the terminal tendon (improving DIPj flexion). In a personal case series of 24 patients treated with serial casting, active flexion improved by 1% in the PIPj and 19% in the DIPj at a mean final treatment visit of 79 days (Range: 41-172) and by 10% in the PIPj and 35% in the DIPj at a mean long-term follow-up of 758 days (Range: 268-1396) (personal data yet to be published). Although based on a small sample, flexion actually seems to improve following conservative treatment without any specific rehabilitation (Fig. 5).

#### *Serial casting (Quickcast® finishing tape)*

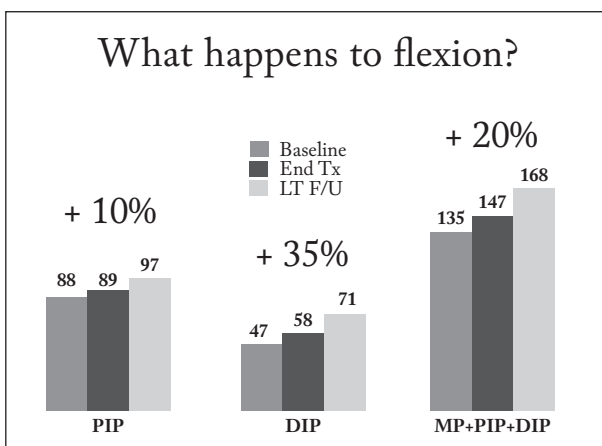
First, measure and note the PIPj passive extension deficit. Then heat the finger(s) (i.e. heat pack, paraffin, warm water, ultrasound, etc.) for 10 minutes while keeping the PIPj in passive extension stretch (Fig. 6) and re-measure. While drying the hand, avoid any flexion at the PIPj. Position the elbow on a table and the hand in an upright position with the fingers spread apart to ease cast application. The patient can participate by using his/her other hand to achieve the desired position. Quickcast® finishing tape is wrapped distal to proximal from below the DIPj skin crease to above the MPj crease (if a pseudo-Boutonnière deformity is present), insuring to overlap the tape at least 50% over itself to insure adequate resistance against the flexing



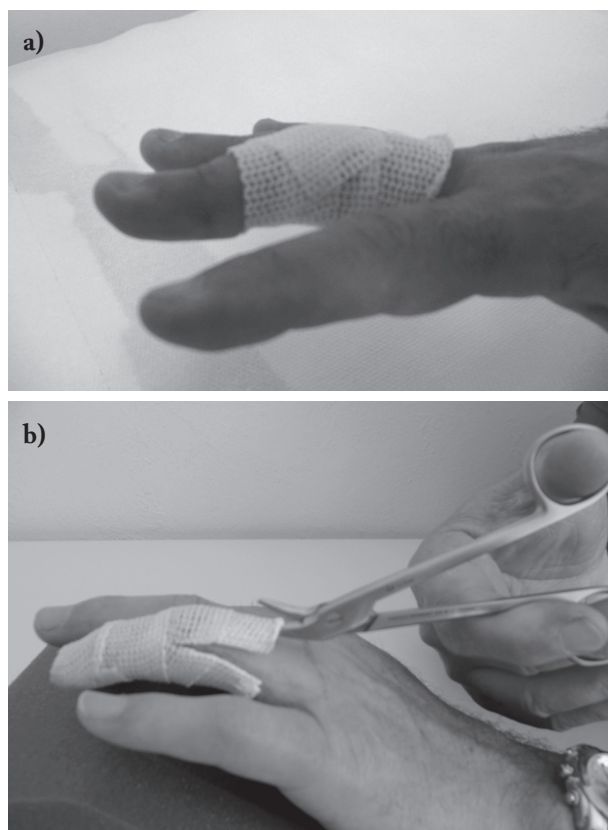
**Figure 6.** PIPj passive extension stretch in warm water with ultrasound (50%, 1 Mhz, 5.0 Watt, 10 minutes)

forces of the joint (Fig. 7a). If DIPj is also contracted into flexion, include the distal phalanx into the cast (Fig. 1a). The manufacturer instructions recommend using a hairdryer (60-70°C) to heat the tape but I prefer a heat gun (300°C) to allow for an extra 5-7 seconds of handling time. Place the cast tape over a towel rather than directly on a tabletop to help disperse the heat more uniformly into the tape. While the QC settles, the therapist's hands apply maximum but comfortable passive stretch of the volar structures of the PIPj. Monitor for discoloration in the distal phalanx once the material has settled for a couple of minutes, and if needed, remove the cast with short beaked cast scissors (Model A37130, Sammons Preston, Bolingbrook, USA) (Fig. 7b) and immediately cast a second time with lower wrapping tension. Inform the patient that a heart beat pulse may be felt in the finger for the first 20-30 minutes after applying the cast. Once the cast is fully hardened, measure the PIPj passive extension deficit again, carefully placing the goniometer arms parallel to the axis of the finger to assess if gains have been made with the casting process.

Repeat this process every 3 days, on average for the first 2 weeks. If complete PIPj passive extension is reached within this time, move on to Step 2. If after 2 weeks there are no gains observed every 3 days, distance the follow-up visits to a week. Keep serially casting until no gains are obtained after 1 month (plateau). We normally move to Step 2 at this stage but some patients may seek full recovery and thus pursue serial



**Figure 5.** Active flexion improvement from baseline to mean long-term follow-up (758 days) in individual joints and all finger joints of 24 patients treated with serial casting (personal data)



**Figure 7.** a) End-result of synthetic casting the stiff PIPj. b) Scissor opening for ease of cast removal when PIPj still flexed beyond 30°

casting. In this case, our suggestion is to keep the PIPj casted for 2-3 weeks without changing casts to give the soft-tissues time to generate new expandable collagen. Then try a few more serial casts. *Note: If this strategy is pursued, the overall length of treatment increases greatly. In our own 15 years experience, regardless of the number of casts applied serially to a PIPj, we never achieved passive extension gains of more than 40°. Thus consider a partial recovery when initially treating contracted joints of more than 45-50°, which is well accepted by patients if the end-active range lies between -20° to 0°.*

### *No-profile static progressive splinting*

Similarly to serial casting, measure and note the PIPj passive extension deficit. Then construct the no-profile SPS as described in the Journal of Hand Therapy practice forum article (14). The orthosis is worn continuously for a minimum of 1-3 days. If full passive extension is not gained at this point, the patient is instructed to wear the orthosis for an additional 2-3 days as long as skin redness is absent over the dorsum of the PIPj. If skin redness is noted at this point, a piece of neoprene or other padding can be added over the PIPj under the Velcro strap to dissipate forces. Full passive extension is usually recovered after this short period if the initial flexion deformity is less than 45° and the no-profile SPS is donned properly (Table 2). It is recommended to spend adequate time educating the patient in avoiding tightening the dorsal Velcro strap beyond skin blanching or fingertip discoloration. If this should occur, the patient should loosen the dorsal strap slightly. Only a light tension on the volar aspect of the PIPj and occasionally on the lateral borders of the joint should be felt. It is therefore preferable to begin with gentle tension and progressively increase the tension. In other words, the concept of TERT (17) is applied through the no-profile SPS. If skin complications are absent and full passive extension is incomplete, the patient should be seen again only once full recovery has been achieved but no later than 2 weeks from the initial visit. Once full PIPj extension has been gained or a plateau has been reached after 2 weeks of usage, move to Step 2.

### *Step 2: Immobilization (Duration: 4-6 Weeks)*

Once maximum PIPj passive extension has been accomplished, an immobilization period is mandatory in order to avoid a rebound effect of the elongated sur-

**Table 2.** Speed of PIPj flexion contracture correction in 10 document cases

	G.C	P.L.R.	E.C.	S.G.	E.P	G.P.	N.P.	C.G.	L.S.	D.B.
Passive PIPj Ext. Deficit@ 1st Visit	-25°	-40°	-35°	-35°	-35°	-35°	-15°	-30°	-35°	-50°
Passive PIPj Ext. Deficit@ Plateau*	0°	0°	0°	0°	-35°	-35°	-15°	-30°	-35°	-50°
Days to reach plateau or full passive PIPj Ext.	3	3	8	16	6	14	7	9	4	4

\* Plateau is considered the maximum passive extension degrees obtained with the non-profile SPS

rounding soft-tissues (3). It is advisable to maintain these elongated structures in their new lengthened position with a static circumferential LTTP orthosis or synthetic cast (Orficast®) (Fig. 2). If LTTP is chosen, consider maceration to be an issue if the patient frequently wets his/her hands or during hot summer days. They should frequently remove their orthosis, which comes with the risk of soft-tissue retraction if the duration of the removal is prolonged more than a few minutes. This is why we prefer using synthetic cast materials as they create none or very little maceration regardless of external temperatures or hand usage. This factor was assessed in another study (18) that compared LTTP orthosis to QC for mallet finger injuries, which is another condition that requires prolonged and continuous orthosis wear, and synthetic cast proved to be less macerating than LTTP. If synthetic cast is chosen for the immobilization phase, it is recommended to replace it every 1-2 weeks during the 4 to 6 week period because of greater wear-and-tear. On the other hand, the LTTP orthosis does not require replacement but follow-up visits should nonetheless be planned every 10-14 days to monitor any rebound effect or orthosis loosening as the finger continues to shrink, if initially swollen.

The duration of the immobilization phase varies according to 3 factors: time of injury onset, severity of stiffness as per the Modified Week's Test (19) and time needed to achieve maximum PIPj extension. If injuries occurred more than 2 months from the initial orthotic corrective visit, we consider it to be in the remodeling phases of repair and the joint may likely be more prone to a rebound effect. Similarly, a rebound effect is to be expected if at initial visit a minimum of at least 10° of passive gains is not achieved following heat modalities and stretching. If these 2 conditions are present the planned immobilization duration after correcting the deformity is 6 weeks rather than 4. When these conditions are absent but 2 or more weeks are needed to passively straighten the joint, especially if the SPS approached was used, we will also immobilize 6 weeks. In all other cases we found that 4 weeks of full immobilization is sufficient to avoid rebound effects.

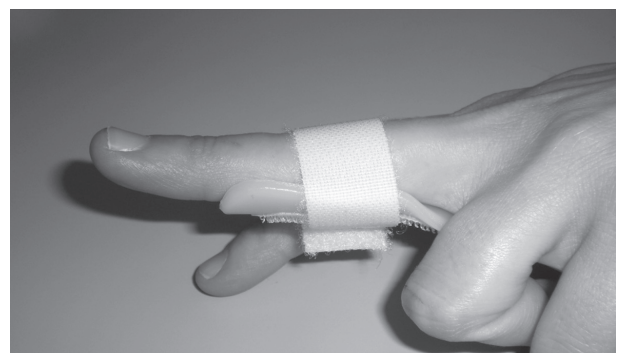
Exercises during the immobilization phase consist in occasional active motion of the DIPj and MPj to mobilize the lateral bands (Fig. 7) but avoid exces-

sive and forceful DIPj flexion as this may create an unwanted DIPj extension lag from overstretching the Oblique Retinacular Ligament (ORL).

### *Step 3: orthosis weaning and flexion recovery*

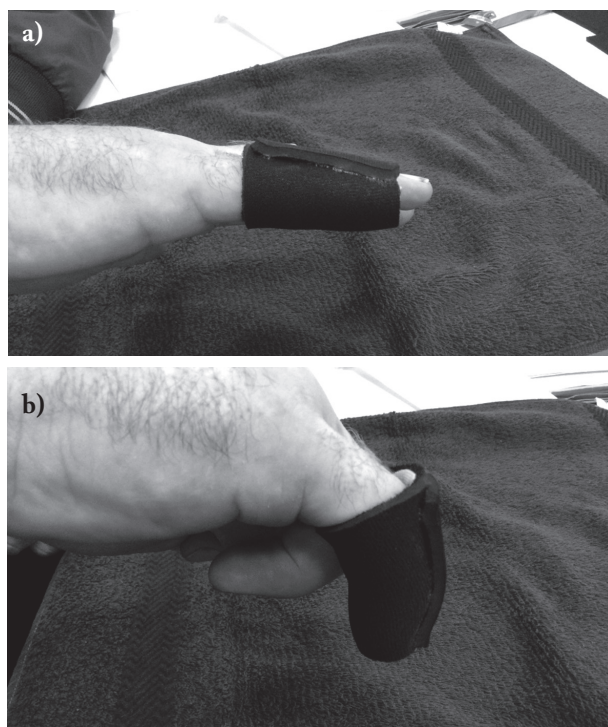
Once the immobilization phase is complete, it is recommended to replace the synthetic cast with a LTTP slab (Fig. 8) as a weaning period begins at this stage. Weaning from the orthosis has to be done progressively and only during the day initially, by adding an extra hour without the orthosis every day. The aim is to leave the finger free during the day after 2-3 weeks and use the orthosis only at night for another 2 weeks. If an extension deficit (>15°) is observed during this phase, restart the immobilization phase (step 2) for another 2-3 weeks while passive correction is still possible. Another strategy is to construct a circumferential neoprene finger sleeve (20) with additional neoprene on the dorsum (Fig. 9) to wear during the day in cases where a rebound effect is expected.

Exercises during the weaning phase consist in 1-2 minute sessions every 3-4 waking hours (4-6 times/day) of intrinsic muscle activation (MPj blocked in flexion while actively extending IPj's) (Fig. 10) and active fist flexion. Passive flexion of the PIPj should be introduced only if no gains have been noted for 2 consecutive weeks, assuming the patient is compliant with his/her home-based exercise program. If patients express difficulty in doing extension block exercises to preserve PIPj extension, a claw deformity orthosis (Fig. 11) can be made for the patient to reproduce the



**Figure 8.** LTTP volar splint used to ease donning and doffing during the weaning phase of the orthotic intervention



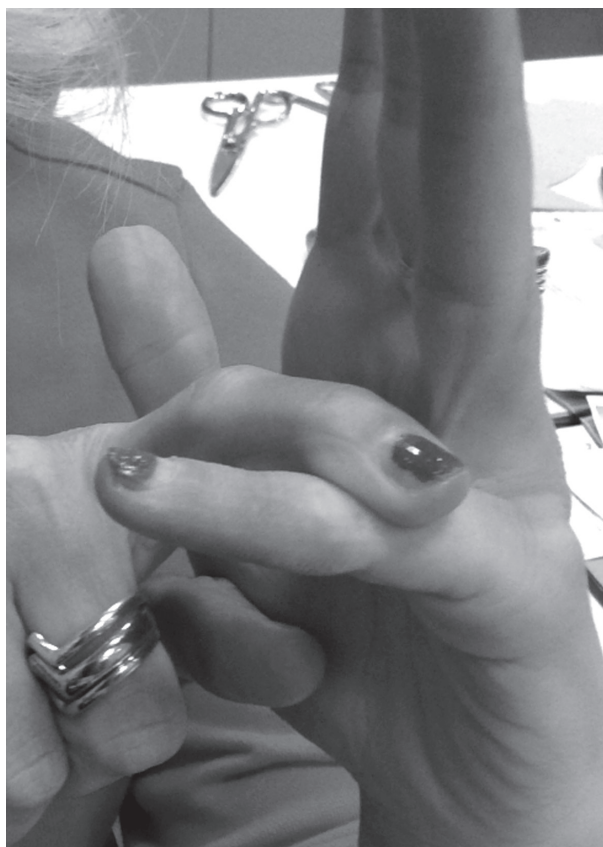

**Figure 9.** Neoprene finger sleeve for daytime wear during the weaning phase. a) Resting position. b) Limited flexion is allowed

exercise and avoid MPj hyperextension especially in the ulnar-sided more mobile fingers.

## Discharge

The decision to discharge a patient that has undergone 2 to 3 months of orthotic corrective management is somewhat challenging. We normally end treatment when PIPj active extension is stable over a 2-week period from the time all orthoses have been dismissed. Flexion may not be fully recovered but long-term follow-ups will surely show improvement especially in the DIPj flexion, which is often more compromised than PIPj flexion with a pseudo-Boutonniere deformity. A small loss of active PIPj extension may also occur over the following months after discharge. This occurs mainly in joints that have not recovered full extension, had residual deficits greater than 30° from neutral or in patients that became incompliant with their home-program during Step 3. Another reason for relapse is related to the absence of the A2 or A4 pulleys, which

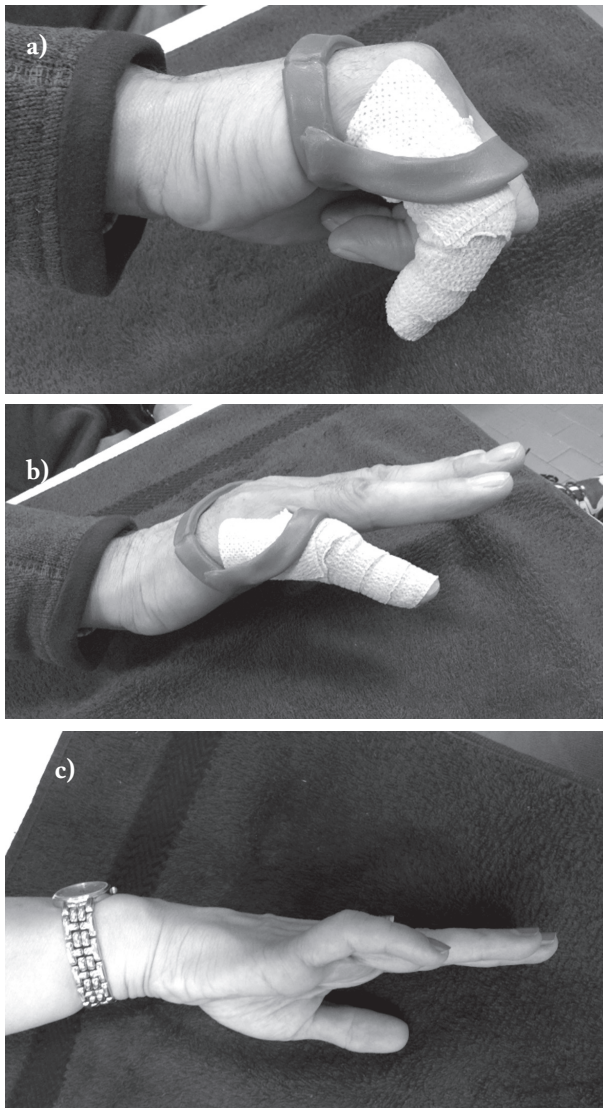


**Figure 10.** Intrinsic muscle reinforcement through MPj blocked passively into flexion while actively extending the IPj's

need to be accounted for prior to treatment. In cases where a relapse of PIPj contracture is feared, the neoprene extension finger sleeve (Fig. 9) may be worn for a month or two after all LTTP orthoses have been discharged.

## Concluding remarks

PIPj flexion contracture is a frequent problem seen by hand therapists and orthopaedic surgeons, and orthotic management is usually the first choice of treatment. Many orthoses can be employed to correct the deformity. Serial casting with synthetic materials and SPS free of outriggers allow patients to don their devices continuously to maximise TERT and gain full or at most 40° of passive PIPj extension within days. Serial casting may take longer to reach the goal of this first step but it is suitable in patients that re-



**Figure 11.** MPj extension orthosis. a) Full flexion is allowed. b) MPj extension is limited to transmit EDC extension force onto the PIPj. c) Flexed PIPj - Hyperextended MPj, the so-called claw deformity

quire full use of their hand during the corrective phase. Once maximum PIPj passive extension has been re-established, avoid any rebound effect and continuously maintain the joint in extension for 4 to 6 weeks with a circumferential LTTP or synthetic cast. Then gradually wean it off while reinforcing the intrinsic muscles of the hand first, and later the extrinsic flexors of the fingers to regain flexion. Weekly follow-ups will allow the therapist to adapt the home-program and ultimately obtain maximum TAM of the finger.

## References

1. Colditz JC, Schneider AM. Modification of the digital serial plaster casting technique. *J Hand Ther* 1995; 8(3): 215-6.
2. Colditz JC. Spring-wire extension splinting of the proximal interphalangeal joint. In: Hunter JM, Mackin EJ, Callahan AD (eds). *Rehabilitation of the Hand and Upper Extremity*, 5th Ed. St. Louis, MO: Mosby Inc., 1995: 1617-29.
3. Colditz JC. Therapist's management of the stiff hand. In: Skirven TM, Osterman AL, Fedorczyk JM, Amadio PC (eds). *Rehabilitation of the Hand and Upper Extremity*, 6th Ed. St. Louis, MO: Mosby Inc., 2011: 894-21.
4. Fess EE. A history of splinting: to understand the present, view the past. *J Hand Ther* 2002; 15(2): 97-132.
5. Campbell PJ, Wilson RL. Management of joint injuries and intraarticular fractures. In: Hunter JM, Mackin EJ, Callahan AD (eds). *Rehabilitation of the Hand and Upper Extremity*. St. Louis, MO: Mosby Inc., 2002: 396-412.
6. Schultz-Johnson K. Static progressive splinting. *J Hand Ther* 2004; 15(2): 163-78.
7. Colditz JC. Efficient mechanics of PIP mobilization splinting. *Br J Hand Ther* 2000; 5(2): 65-71.
8. Cantero-Télez R, Cuesta-Vargas AI, Cuadros-Romero M. Treatment of Proximal Interphalangeal Joint Flexion Contracture: Combined Static and Dynamic Orthotic Intervention Compared With Other Therapy Intervention: A Randomized Controlled Trial. *J Hand Surg* 2015; 40(5): 951-55.
9. Flower KR. A proposed decision hierarchy for splinting the stiff joint, with an emphasis on force application parameters. *J Hand Ther* 2002; 15: 158-162.
10. Puértolas S, Pérez-García JM, Gracia L, Cegoñino J, Ibarz E, Puértolas JA, Herrera A. Design of splints based on the NiTi alloy for the correction of joint deformities in the fingers. *Biomed Eng Online* 2010; 13: 9-49.
11. Flower KR, LaStayo P. Effect of total end range time on improving passive range of motion. *J Hand Ther* 1994; 7: 150-157.
12. Fess EE. A history of splinting: to understand the present, view the past. *J Hand Ther* 2002; 15(2): 97-132.
13. Brand P. Lessons from hot feet: a note on tissue remodeling. *J Hand Ther* 2002; 15(2): 133-5.
14. Boccolari P, Tocco S. Alternative splinting approach for proximal interphalangeal joint flexion contractures: no-profile static-progressive splinting and cylinder splint combo. *J Hand Ther* 2009; 22(3): 288-93.
15. Villeco JP. Edema: Therapist's Management. In: Skirven TM, Osterman AL, Fedorczyk JM, Amadio PC (eds). *Rehabilitation of the Hand and Upper Extremity*, 6th Ed. St. Louis, MO: Mosby Inc., 2011: 845-57.
16. Taras JS, Martyak GG, Steelman PJ. Primary Care of Flexor Tendon Injuries In: Skirven TM, Osterman AL, Fedorczyk JM, Amadio PC (eds). *Rehabilitation of the Hand and Upper Extremity*, 6th Ed. St. Louis, MO: Mosby Inc., 2011: 445-56.
17. Flowers KR, LaStayo P. Effect of total end range time. *J Hand Ther* 1994; 7(3): 150-7.

18. Tocco S, Boccolari P, Landi A, Leonelli C, Mercanti C, Pogliacomi F, Sartini S, Zingarello L, Nedelec B. Effectiveness of cast immobilization in comparison to the gold-standard self-removal orthotic intervention for closed mallet fingers: a randomized clinical trial. *J Hand Ther* 2013; 26(3): 191-200.
19. Flowers KR. A proposed decision hierarchy for splinting the stiff joint, with an emphasis on force application parameters. *J Hand Ther* 2002; 15(2): 158-62.
20. Clark EN. A preliminary investigation of the neoprene tube finger extension splint. *J Hand Ther* 1997; 10(3): 213-21.

---

Correspondance:

Silvio Tocco

Centro Riabilitativo della Mano e Arto Superiore,

Via Marconi 45 (Sede Legale)

43035 Fornovo Taro (PR), Italy

Mobile phone: 00393387090316

E-mail: [silvio.tocco@me.com](mailto:silvio.tocco@me.com)