

R E V I E W

Weight-bearing MRI of the knee: a review of advantages and limits

Federico Bruno¹, Antonio Barile¹, Francesco Arrigoni¹, Antonella Laporta², Anna Russo³, Marina Carotti⁴, Alessandra Splendiani¹, Ernesto Di Cesare¹, Carlo Masciocchi¹

¹Department of Biotechnology and Applied Clinical Sciences, University of L'Aquila, L'Aquila, Italy; ²Department of Radiology, Solofra Hospital, Avellino, Italy; ³Department of Radiology, University of Campania "Luigi Vanvitelli", Naples, Italy; ⁴Azienda Ospedaliera Universitaria, Ospedali Riuniti di Ancona, Dipartimento di Scienze Radiologiche S. O. D. Radiologia Pediatrica e Specialistica, Ancona

Summary. Standard knee imaging with MRI is usually performed with patient in recumbent position under non-weight-bearing conditions. Recently, magnetic resonance imaging systems to scan the knee joint under weight bearing conditions has been proposed as an approach to improve the clinical utility of musculoskeletal MRI. Imaging under loading can be useful to understand the natural motion behavior of the knee joint and to identify conditions that are challenging to diagnose by using standard position. We reviewed the literature on weight-bearing MR imaging of the knee to describe the current state of use of such MRI technologies, evaluating the advantages and the potential limitations of these technologies. (www.actabiomedica.it)

Key words: Magnetic Resonance Imaging, weight-bearing MRI, knee pathology

Introduction

Magnetic resonance imaging (MRI) has emerged as the imaging modality of choice for the majority of musculoskeletal disorders, and the development of MRI technologies is still nowadays an active field of research (1-21). Compared to CT, MRI allows a radiation-free evaluation of bone and soft tissues with a high contrast resolution and has proved to be a useful tool not only for diagnostic purpose but also for image-guided interventional radiology procedures (22-34). Conventional knee MRI is normally performed in standard supine position under non-weight-bearing conditions (35). However, the evaluation of knee joint modifications under physiological weight-bearing conditions is necessary to understand the natural motion behavior of the knee joint. Moreover, MRI under loading stress may be useful for identifying conditions that are challenging to diagnose by using

standard MRI, such as cases in which patients manifest symptoms only in certain positions or only with weight bearing (35-45). Recently, magnetic resonance imaging under loading stress has been proposed as an approach to improve the clinical utility of musculoskeletal MRI. Using closed-tunnel MR facilities this evaluation is limited by the physical constraints that do not allow adequate weight-bearing, and are therefore unlikely to mimic the in vivo changes of the joint structures (46-55).

Dedicated open MR units (0.25T to 0.6 T) systems have been designed to overcome these limits of conventional MRI scanners. The WB-MRI weight-bearing MRI (WB-MRI) having already proved to be extremely valuable in the evaluation of dynamic alterations of the spine (56-61). In such systems, the bore is typically oriented laterally, with the magnets placed to allow an image to be obtained in weightbearing positions (that is, under loading stress) in which the patient

is positioned standing upright or sitting (fig. 1). Such configurations also allow for flexion and extension views to be obtained (“multipositional MRI”). These devices can be used with minimal additional training by MRI facility personnel, and they do not require any specialized installation compared with standard scanners (62–65). Imaging under loading stress can alternatively be obtained by placing an axial force on the patient lying supine in a conventional MRI scanner. This approach attempts to simulate gravity by using the compressive force of cords connected to a vest that pull the patient’s upper body against a fixed footplate while knees remain in the extended position. Due to the higher availability of closed-bore scanners compared to upright open-bore scanners, these systems have been widely used as an alternative to upright weight-bearing measurements.

Scientific questions arising in the study of clinical issues such as the initiation and progression of knee osteoarthritis (OA), the effectiveness of joint reconstruction surgeries, and the origins of patellofemoral pain, have motivated the development of techniques

for functional in vivo investigations of the knee joint. We reviewed the literature on weight-bearing MR imaging of the knee to describe the current state of use of such MRI technologies. We also enumerate the potential benefits and limitations of these technologies to describe the evidence available to date that supports their clinical application.

Tibio-femoral compartment

Magnetic resonance imaging (MRI) is favourably suited to the study of femoro-tibial relations as it allows precise imaging of the medial and lateral compartments of the knee (47).

ACL insufficiency

The long term sequelae of ACL insufficiency has a high incidence of degenerative osteoarthritis particularly in the medial compartment. Abnormal kin-

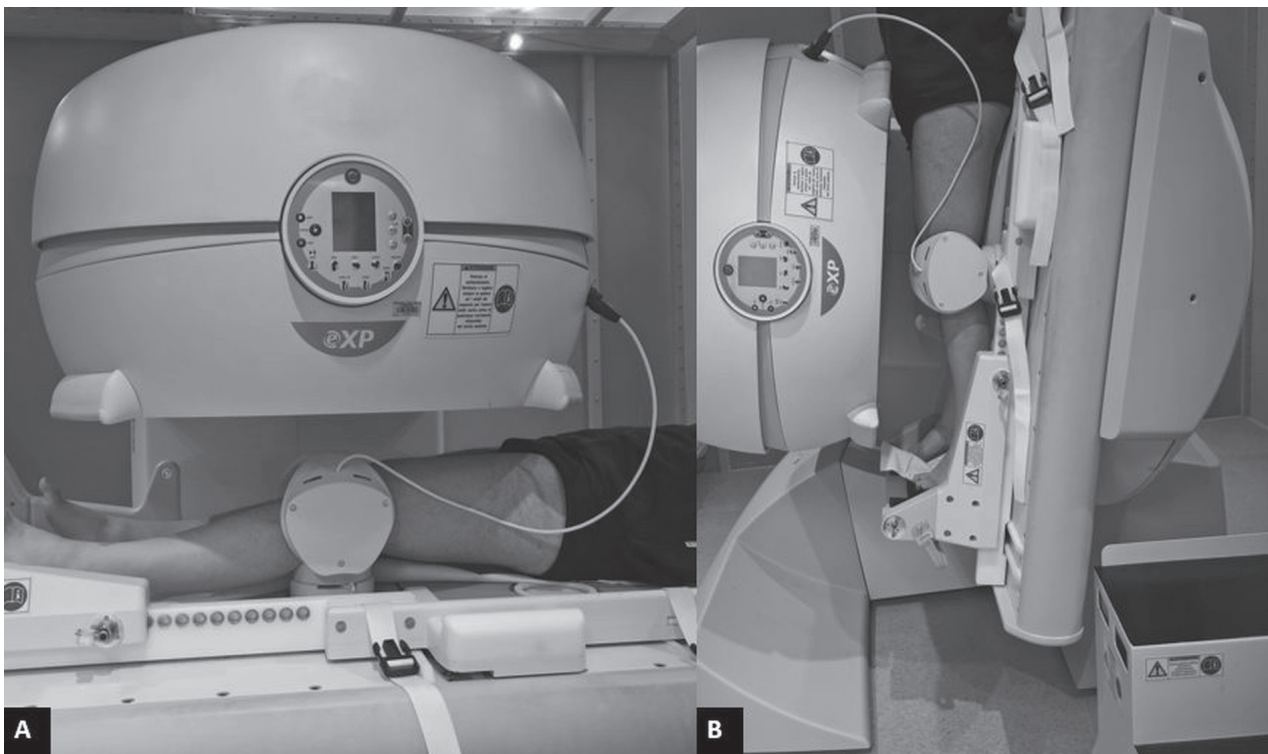


Figure 1. Open low-field scanner for weight-bearing imaging of the knee in standard supine (A) and upright configuration (B), after table tilt of about 82°

ematics persisting after the principal injury is thought to produce pathological laxity and abnormal loading environment and risk further meniscal injury. Several authors investigated the possible role of weight bearing MRI for evaluating ACL deficiency. Two measurement techniques have been explored examining normal and ACL-deficient knees: the flexion facet centre technique (FFC), based on definition of the centre rotation of the posterior femoral condyle, and the femoro-tibial contact point technique (FTCP), that maps the articulation position of joint surface contact. Translation of the joint is defined by both techniques in reference to the posterior tibial plateau.

Nicholson et al. evaluated the validity of these measurements in patients with pathological knee laxity after ACL rupture in an upright open MRI scanner (36). Anterior displacement of the tibia was observed in all ACL-deficient knees in comparison to the contralateral knee (fig. 2). In the ACL-deficient knee the medial tibial plateau was found to be anteriorly displaced, relative to that of the respective control in the contralateral knee, in extension and during flexion. The greater subluxation of the lateral tibial plateau compared to smaller change in the medial side constitutes excessive internal rotation of the tibia on the femur during early angles of flexion. FFC recordings were easier to obtain with greater repeatability, indicating they hold an advantage over FTCP.

Meniscus evaluation

There is a complex interaction between the tibiofemoral joint and meniscal kinematics, with meniscal translation also combining with meniscal distortion from compression of the femoral condyle on the menisci (55). Meniscal diseases are commonly studied by means of MRI which allows evaluation of meniscal injuries with high sensitivity and specificity (50)

Lustig et al. (55) tried to investigate determine the effects of flexion angle on meniscal slope during partial weight-bearing knee flexion examining 15 healthy individuals. The bed was tilted 30° to the horizontal, and the patient was asked to slide down into a squat position with maximum tolerable knee flexion. Pilot testing confirmed application of 20% to 25% body weight to each foot. The scans were repeated for both knees at 60° and full extension. The sagittal plane section in the middle of each tibial plateau was used for measurement of bony slope (BS) and meniscal slope (MS). The key findings confirmed the hypothesis that the meniscal slope increases in both compartments during knee flexion and is significantly greater for the lateral meniscus than for the medial meniscus. The significant increase in meniscal slope for both compartments matches well with a potential decrease in load on the anterior horn and concomitant increase on the posterior horn with flexion. The findings confirm a differ-

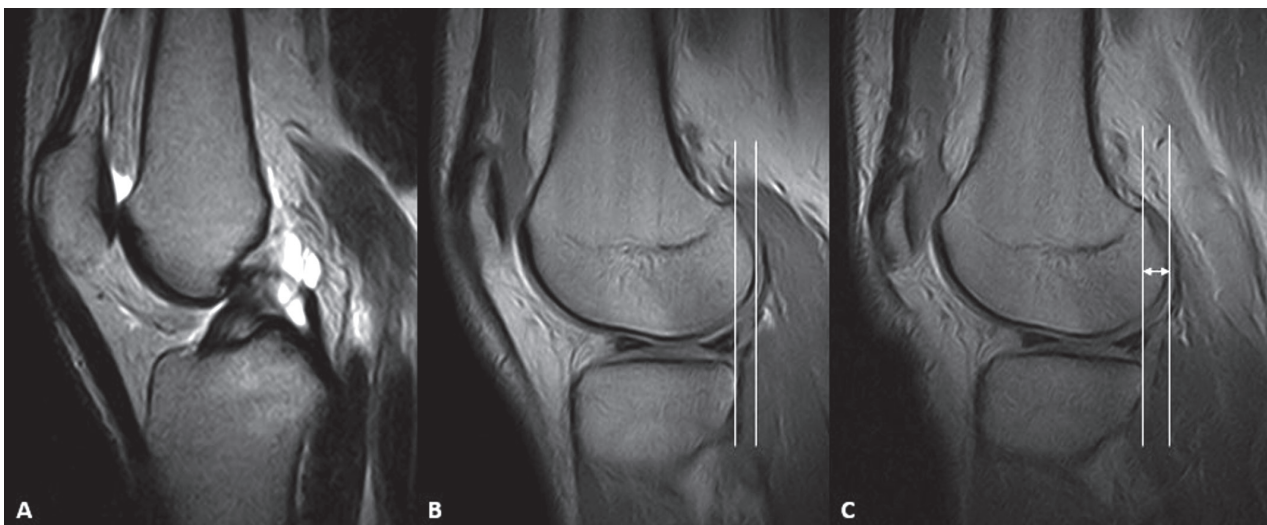


Figure 2. Sagittal MRI images of the knee of a patient with ACL rupture in standard supine (A, B) and weight bearing position (C): we can appreciate the anterior tibial translation (red arrows), as a sign of ACL insufficiency under load condition

ence between compartments regarding meniscus slope changes throughout range of motion. Clinically, this could be used to assess the results after meniscal repair, potentially leading to new suture methods, with particular emphasis on the functional differences between the medial and lateral menisci.

Barile et al. (50) evaluated 57 patients with meniscal injuries (both degenerative, traumatic tears and meniscocapsular separation). Employing the weight-bearing MR they evaluated the meniscal morphology and signal intensity load-induced variations, and meniscal extrusion on a coronal plane. Arthroscopy confirmed in every case the diagnosis obtained by weight-bearing MRI. In their results, weight-bearing MRI always depicted unstable lesions. In these cases, during the passage from supine and upright position, a modification of the meniscal morphology was constantly present, resulting in a posterior subluxation of the posterior horn of the medial meniscus (fig. 3). This phenomenon can be well appreciated on sagittal

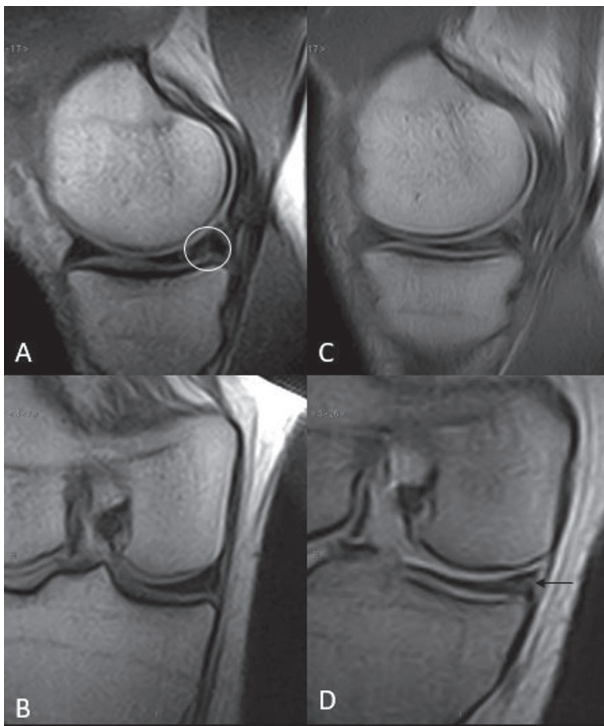


Figure 3. Sagittal and coronal MRI images of the knee in standard supine (A, B) and weight-bearing upright position (C, D). Note how the posterior horn meniscal tear (white circle) becomes more evident under weigh-bearing (black arrow), finding consistent with an unstable tear

scan planes in which the posterior horn of the medial meniscus loses its congruity with the tibial plateau. Otherwise, morphological modifications and posterior subluxation of the posterior horn of the medial meniscus, were not present in stable lesions.

Other findings

Tibiofemoral kinematics evaluation is also important for the assessment of OA symptoms, that are dependent on specific movement and weight-bearing patterns (53). A mechanism for pain relief through functional unloading of the medial tibiofemoral compartment with in-shoe orthoses has been proposed (54). Barrance et al. (54) studied using a 0.6T open scanner the effects of an external lateral shoe wedge, as well as the effects of knee flexion angle, on several descriptors of contact. The nylon heel wedges could be rotated to provide neutral (0°) and 5° lateral wedging conditions. Subjects were scanned in two angles of knee flexion: neutral (0° flexion) standing in full weightbearing, and a bilateral, full weightbearing squat at 20° knee flexion. A small but significant effect of lateral wedging on lateral condyle contact location was observed, while knee flexion had clear and consistent effects on contact parameters. Both contact locations moved posteriorly when moving from extension to flexion. Comparing between compartments, they observed considerably greater posterior movement of the contact area in the lateral condyle. This study provided evidence that lateral heel wedging produces an anterior shift of the contact patch of the lateral femoral condyle on the tibial plateau, in the flexed weight bearing knee.

Normal kinematics of the anterior interval is essential for pain free, full knee motion. Abnormalities have impact on patello-femoral kinetics and kinematics, possibly causing long-term chondral damage (66). Significant changes in fat pad shape and position occur during the full arc of knee flexion. These changes require the anterior interval structures to open and close to allow normal movement of the fat pad and to prevent impingement. In extension, part of the fat pad fills the anterior interval but in flexion it is completely extruded as the potential space closes. Failure to achieve this may lead to impingement of remain-

ing fat pad in the anterior tibio-femoral articulation or patello-femoral joint and may lead to significant infrapatellar pain (66). Dragoo et al. tried to quantify, with dynamic MRI, the relative kinematic changes of two structures of the anterior interval, the patellar tendon and the anterior border of the tibia, throughout a full range of motion (30° intervals from 0° to 120° flexion) (67). Authors observed a decrease in the patellar tendon-tibial angle (PTTA) with increasing degrees of knee flexion in both full-weight bearing and non-weight bearing conditions; the magnitude of the decrease was significantly different in these two conditions. Under full-weight bearing, the average patellar tendon-tibial angle at full extension was 33°, which is nearly 28% less than the 45° observed in non-weight bearing conditions.

They concluded that the impact of load on the mechanics of the anterior interval is most pronounced near full extension. The difference in patellar tendon excursion found between full-weight bearing and non-weight bearing conditions may have clinical implications; for example, a 1-2 week period of non-weight bearing after anterior interval release procedures may decrease the apposition of the released edges of the scarred infrapatellar fat pad, which may decrease the incidence of re-scarring.

Patello-femoral compartment

Patellofemoral (PF) pain is a common and debilitating disorder that typically arises during activities that place high loads across the joint, such as squatting, and running (68).

Unfortunately, effective treatment is challenging because the underlying causes of pain are often unclear. Furthermore, multiple biomechanical factors likely contribute to the development of pain.

Patellofemoral joint kinematics can change with quadriceps contraction and joint loading (69). Although there are several causes of PF pain, patella alta, or high-riding patella, is thought to predispose individuals to PF pain. A high-riding patella is theorized to engage the femoral trochlear groove at a greater knee flexion angle, resulting in less medial-lateral constraint of the patella and lateral patellar maltracking at

low knee flexion angles. Lateral patellar maltracking is theorized to decrease PF contact area and increase joint stress, resulting in pain (69). Elevated cartilage stress of the patellofemoral joint is hypothesized to play a role in the onset of pain. Estimating cartilage stress requires accurate measurements of contact area (49).

Accurate diagnosis is important because the underlying cause of pain may differ between a patient with maltracking compared to one with normal patellofemoral kinematics. Treatments that address the specific nature of a patient's pain may be most effective (70).

Several parameters to define factors for abnormal tracking of the patella relative to the femur have been quantified:

Insall-Salvati index (IS): the ratio of the patellar tendon length divided by the diagonal length of the patella (normal value: 0.8-1.2)

Lateral patellar displacement (LPD): the distance from the medial edge of the patella to a line drawn perpendicular to the posterior condylar line and passing through the most anterior point of the medial condyle (normal value: 2mm+/-1)

Lateral patello-femoral angle (LPA): the angle formed between a line drawn parallel to the lateral patellar facet and a line connecting the most anterior points of the medial and lateral condyles (normal value: 13°+/-5)

Lateral patellar tilt (LPT): the angle formed between the posterior condylar line and a line drawn through the maximum width of the patella (normal value: 5°+/-2)

Caton Dechamp index: the distance from the anterosuperior border of the tibial plateau to the distal end of the patellar cartilage relative to the length of the patellar articular cartilage. Larger values indicate a higher position of the patella relative to the tibia (71)

Patello-trochlear index: measure of patellar height relative to the femoral trochlea by calculating the ratio of the length of the patellar cartilage and the femoral trochlear articular cartilage overlapping the patellar cartilage. It is reported as a percentage, with larger values indicating a larger contact area between the patellar and trochlear cartilage (71).

Patello-trochlear angle: the angle between the patella and the posterior femoral condyles. Larger values

indicate increased external rotation of the patella relative to the femur.

Bisect offset: a measure of patella medial–lateral translation, is reported as the percentage of the patella lateral to the midline of the femur. Larger values indicate a more lateralized position of the patella relative to the femur (70).

Tibial tuberosity–trochlear groove (TT-TG) distance: used to quantify the alignment of the extensor mechanism. It is defined as the distance between the midpoint of the patellar tendon insertion at the tibial tuberosity and the first craniocaudal transverse slice that depicts complete cartilaginous trochlear coverage. Larger values indicate increased malalignment with increased lateral force displacement of the patella (71). Distances exceeding 15 or 20 mm are generally considered pathological and indication for operative medialization of the tibial tubercle in symptomatic patients (70).

Blackburne–Peel index: the ratio of the perpendicular distance from a line drawn along the tibial plateau to the distal point of the patellar articular cartilage and patellar cartilage length (68).

Imaging assessment, however, is usually undertaken with the patient supine under non-weight bearing conditions without quadriceps activation. Thus, treatments are often based on indices that were defined under non-weight bearing conditions (71). Differences in patellofemoral alignment and tracking under loaded conditions must be adequately addressed to understand the pathology of this diagnosis and thus to establish the appropriate treatment (71). Upright MRI scans allow for a comprehensive investigation to understand how patellofemoral joint contact area changes with weight-bearing in different knee postures (48).

Draper et al. (69) investigated the effects of loading in patellofemoral contact area studying 16 subjects with an open configuration MRI scanner, which allowed subjects to stand or squat while reclining 25° from vertical with the knee positioned at 0°, 30°, or 60° of flexion. Male subjects displayed mean unloaded patellofemoral joint contact areas of 210, 414, and 520 square mm at 0°, 30° and extension, but significantly smaller at 30° and 60°. When normalized by patellar dimensions (height x width), contact areas were not different between genders. Under weight-bearing con-

ditions, contact areas increased by an average of 24% (49). They concluded that greater loading is likely to result in greater cartilage deformation and lead to increased contact area.

The same authors evaluated whether patellofemoral joint kinematics differ between upright, weight-bearing and supine, non-weight-bearing loading conditions in patients with patellofemoral pain (62). 20 patients diagnosed with patellofemoral pain were scanned during dynamic, active knee extension in two different loading conditions: upright, weight-bearing and supine, with no application of external joint loads. Active quadriceps contraction was required for both conditions. They detected differences in the lateral translation of the patella relative to the femur between upright, weightbearing and supine, non-weight-bearing knee extension (fig. 4). The bisect offset during the supine task was 5% larger than that during the weight-bearing task. Patellar tilt was not affected by loading condition in either population Non-weight-bearing

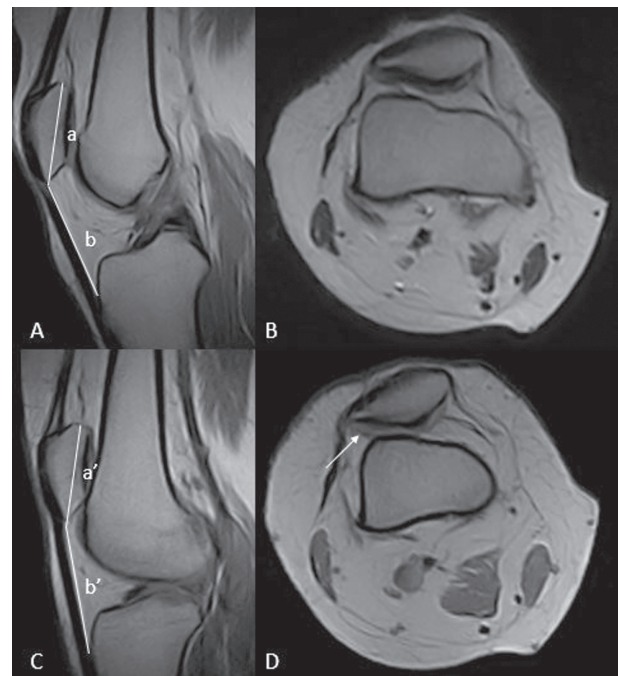


Figure 4. Sagittal and axial MRI images of the knee in standard supine (A, B) and weight-bearing position (C, D) of a patient with a high riding patella and patello–femoral instability. Under loading conditions, we can appreciate increase of the Insall–Salvati index (b/a ratio: 1.3; b'/a' ratio: 1.6) and lateral patellar subluxation (white arrow)

motion produced more lateral patellar translation than weightbearing motion in normal trackers, but the opposite was found in patients with excessive lateral patellar translation. Thus, patients with normal patellar translation during functional, weight-bearing tasks may present with excessive lateral patellar translation near terminal extension during a supine, non-weight-bearing clinical assessment task.

Mariani et al. (68) evaluated 95 patient with clinically suspected patellofemoral maltracking; both knees in the weight-bearing position were under physiological load (about 5-12° of knee flexion) with the table tilted to 82°. In each patient they evaluated the Insall-Salvati index (IS), the lateral patellar displacement (LPD), the lateral patello-femoral angle (LPA) and the lateral patellar tilt (LPT). Patients negative to clinical tests didn't show differences of the patellofemoral indices between standard and weight-bearing examinations. Patients positive to clinical test showed alteration of 1 or more indices at the MR examination, both standard and weight bearing. Among measurements, the most reliable in unmasking a patello-femoral maltracking, passing from the standard to the WB-MRI exam, was the LPT.

Becher et al. (71) analysed the effects of upright weight bearing and the knee flexion angle on patellofemoral indices, in 16 patients with patellofemoral instability (PI). The subjects were first examined in upright weight bearing position at full extension (0°) and at 15°, 30°, and 45° flexion. Patellofemoral MRI indices in PI patients were affected by upright weight bearing and the flexion angle compared with healthy controls. With weight bearing, parameters for patellar height, the PTA, and the BO were increased at full extension. Independent of weight bearing, flexing the knee reduces the PTA, BO, and TT-TG distance, with approximation of values at 45° flexion. Significant differences with higher patellar position in the PI group compared with the control group independent of weight bearing were observed at 30° and 45° flexion. Independent of weight bearing, flexing the knee revealed significantly reduced values in both groups among patients with approximation of values for the PTA, BO, and TT-TG at 45° flexion.

Pal et al (70) evaluated 37 subjects with chronic PF pain. Subjects were assisted by a custom-built

backrest that required a subject to support about 90% of his/her bodyweight. They measured patella height from sagittal plane images acquired during the upright, weightbearing MRI at 5° knee flexion, Caton Dechamp, Insall Salvati and Modified Insall Salvati, Blackburne-Peel index. They also measured patellar tilt and bisect offset, patellar tracking measures. Lateral patellar maltracking was more prevalent among PF pain subjects with patella alta compared to PF pain subjects with normal patella height. Average patella height was greater in all PF pain subjects grouped together compared to all pain free subjects. Average patellar tilt was greater in PF pain subjects with patella alta compared to PF pain subjects with normal patella height. They found greater percentage of patellar maltracking among the PF pain subjects with patella alta compared to PF pain subjects with normal patella height. They concluded that clinical evaluation of PF pain subjects should include measurement of patellar tracking and patella height under weightbearing conditions prior to selection of a treatment pathway.

Izadpanah et al. (72) evaluated the influence of different joint positions which are potentially available for MRI scans of the TTTG distance. In lying and upright positions, images were acquired at 0° and 30° knee flexion. A significant increase in the TTTG distance was found in full extension compared to a 30° flexion position. Additionally, a significant influence of weight-bearing and consecutive quadriceps activation on TTTG distance in 0° flexion position, but not in 30° flexed knee joint was found (72). Concerning clinical relevance of the study, the most important finding was that flexion angle, on the one hand, and muscle activation, on the other hand, significantly affect TTTG distance and therefore have to be considered in patients in which TTTG distance is analysed as a parameter for the determination of patellofemoral alignment. Thus, for example, the preoperative planning of a tuberositas medialization, which is a pure bony procedure, should be carried out on images taken at 30° knee flexion to exclude the influence of muscle activation. Second is to sensibilize on the influence of weight bearing, which only influences TTTG in 0° position, but not in 30° flexion.

Limitations

Despite the encouraging clinical results described above, there are several limitations in the application of dynamic, weight-bearing MRI that make its use challenging in routine clinical practice (69, 73).

One of the general disadvantage of state-of-art approaches for in vivo knee kinematic measurement is that the joint is evaluated under static, upright, weight bearing conditions, which do not fully reflect the dynamic flexion kinematics of the lower limb. Although more physiological upright loading has been achieved in recent studies, the use of inclined supporting backrests remains, however, a limitation (46, 73, 74). Since current upright scanners prevent full vertical position, backrests must usually be inclined backwards to ensure comfortable stance during image acquisition. However, it is questionable to what extent the body weight is supported by the backrest. Moreover, joint scans are most often performed in bipedal stance, which is inadequate for studying physiological knee loading in other situations where the body weight is completely transferred onto one leg, for example, during the stance phase in walking or stair climbing (46, 71). Moreover, because of the long acquisition time and the pain reported by the patients in some cases, some authors reported that it is not always possible to apply more than 25% of body weight through the foot, especially for 90° and maximum flexion (54, 55).

Patient discomfort is one of the main concerns in weight bearing imaging of the knee, as subject movement significantly degrades images in MRI scanning. Such motions are likely to increase with the scan duration and when voluntary muscle contraction is required to maintain a weight-bearing position (75). Gade et al. (75) proposed a methodology using MRI-compatible sensing technology to provide visual position feedback to assist in maintaining a stationary posture during fully upright weight-bearing scanning. Their study demonstrated diminished task performance associated with increasing knee pain severity. This study supported the feasibility of weight-bearing MRI studies using imaging protocols of shorter time duration, in patients with mild to moderate knee pain, and providing adequate rest periods to minimize the effects of fatigue.

Another important limitation of weightbearing (upright) MRI devices is the of low magnetic field strength (<1 T) on the image quality (48), and the current limited availability of upright- MRI scanners in the clinical setting .

Conclusion

Our review of the literature suggests that weight bearing MRI of the knee is an area of active research. Despite several limitations, imaging in non-recumbent position under physiological stress allows detection of load-induced physiological and pathological variations. The most relevant results up to date showed that this new diagnostic instrument allows to recognize both the meniscal tear stability and a latent instability, making it possible to correctly guide the orthopaedic surgeon towards the treatment management. Moreover, upright MRI allows to accurately understand patellofemoral kinematics during painful activities, helping to differentiate maltrackers from nonmaltrackers and to improve treatment for patellofemoral pain.

References

1. Barile A, Sabatini M, Iannesi F, Di Cesare E, Splendiani A, Calvisi V, Masciocchi C. Pigmented villonodular synovitis (PVNS) of the knee joint: magnetic resonance imaging (MRI) using standard and dynamic paramagnetic contrast media. Report of 52 cases surgically and histologically controlled. *Radiol Med* 2004; 107: 356-66.
2. Masciocchi C, Lanni G, Conti L, Conchiglia A, Fascetti E, Flamini S, Coletti G, Barile A. Soft-tissue inflammatory myofibroblastic tumors (IMTs) of the limbs: Potential and limits of diagnostic imaging. *Skelet Radiol* 2012; 41: 643-649.
3. Ripani M, Continenza MA, Cacchio A, Barile A, Parisi A, De Paulis F. The ischiatic region: normal and MRI anatomy. *J Sports Med Phys Fitness* 2006; 46: 468-75.
4. Masciocchi C, Arrigoni F, Ferrari F, Giordano AV, Iafrate S, Capretti I, Cannizzaro E, Reginelli A, Ierardi AM, Floridi C, Angileri AS, Brunese L, Barile A. Uterine fibroid therapy using interventional radiology mini-invasive treatments: current perspective. *Med. Oncol* 2017; 34:
5. Barile A, La Marra A, Arrigoni F, Mariani S, Zugaro L, Splendiani A, Di Cesare E, Reginelli A, Zappia M, Brunese L, Duka E, Carrafiello G, Masciocchi C. Anaesthetics, steroids and platelet-rich plasma (PRP) in ultrasound-guided musculoskeletal procedures. *Br J Radiol* 2016; 89:

6. Barile A, Bruno F, Arrigoni F, Splendiani A, Di Cesare E, Zappia M, Guglielmi G, Masciocchi C. Emergency and Trauma of the Ankle. *Semin Musculoskelet Radiol* 2017; 21: 282-289.
7. Zappia M, Castagna A, Barile A, Chianca V, Brunese L, Pouliart N. Imaging of the coracoglenoid ligament: a third ligament in the rotator interval of the shoulder. *Skelet Radiol* 2017; 46: 1101-1111.
8. Arrigoni F, Barile A, Zugaro L, Splendiani A, Di Cesare E, Caranci F, Ierardi AM, Floridi C, Angileri AS, Reginelli A, Brunese L, Masciocchi C. Intra-articular benign bone lesions treated with Magnetic Resonance-guided Focused Ultrasound (MRgFUS): imaging follow-up and clinical results. *Med Oncol* 2017; 34:
9. Reginelli A, Zappia M, Barile A, Brunese L. Strategies of imaging after orthopedic surgery. *Musculoskeletal Surg* 2017; 101:
10. Barile A, Arrigoni F, Zugaro L, Zappia M, Cazzato RL, Garnon J, Ramamurthy N, Brunese L, Gangi A, Masciocchi C. Minimally invasive treatments of painful bone lesions: state of the art. *Med Oncol* 2017; 34:
11. Di Pietto F, Chianca V, de Ritis R, Cesarano E, Reginelli A, Barile A, Zappia M, Ginolfi L. Postoperative imaging in arthroscopic hip surgery. *Musculoskeletal Surg* 2017; 101: 43-49.
12. Barile A, Bruno F, Mariani S, Arrigoni F, Brunese L, Zappia M, Splendiani A, Di Cesare E, Masciocchi C. Follow-up of surgical and minimally invasive treatment of Achilles tendon pathology: a brief diagnostic imaging review. *Musculoskeletal Surg* 2017; 101: 51-61.
13. Barile A, Bruno F, Mariani S, Arrigoni F, Reginelli A, De Filippo M, Zappia M, Splendiani A, Di Cesare E, Masciocchi C. What can be seen after rotator cuff repair: a brief review of diagnostic imaging findings. *Musculoskeletal Surg* 2017; 101: 3-14.
14. De Filippo M, Pesce A, Barile A, Borgia D, Zappia M, Romano A, Pogliacomini F, Verdano M, Pellegrini A, Johnson K. Imaging of postoperative shoulder instability. *Musculoskeletal Surg* 2017; 101: 15-22.
15. Splendiani A, Bruno F, Patriarca L, Barile A, Di Cesare E, Masciocchi C, Gallucci M. Thoracic spine trauma: advanced imaging modality. *Radiol. Med* 2016; 121: 780-792.
16. Masciocchi C, Arrigoni F, Marra AL, Mariani S, Zugaro L, Barile A. Treatment of focal benign lesions of the bone: MRgFUS and RFA. *Br J Radiol* 2016; 89:
17. Ferrari F, Arrigoni F, Miccoli A, Mascaretti S, Fascetti E, Mascaretti G, Barile A, Masciocchi C. Effectiveness of Magnetic Resonance-guided Focused Ultrasound Surgery (MRgFUS) in the uterine adenomyosis treatment: technical approach and MRI evaluation. *Radiol Med* 2016; 121: 153-161.
18. Arrigoni F, Barile A, Zugaro L, Fascetti E, Zappia M, Brunese L, Masciocchi C. CT-guided radiofrequency ablation of spinal osteoblastoma: treatment and long-term follow-up. *Int J Hyperthermia* 2017; 1-7.
19. Cazzato RL, Garnon J, Ramamurthy N, Koch G, Tsoumakidou G, Caudrelier J, Arrigoni F, Zugaro L, Barile A, Masciocchi C, Gangi A. Percutaneous image-guided cryoablation: current applications and results in the oncologic field. *Med. Oncol* 2016; 33:
20. Limbucci N, Rossi F, Salvati F, Pistoia LM, Barile A, Masciocchi C. Bilateral Suprascapular nerve entrapment by glenoid labral cysts associated with rotator cuff damage and posterior instability in an amateur weightlifter. *J Sports Med Phys Fitness* 2010; 50: 64-67.
21. Barile A, Regis G, Masi R, Maggiori M, Gallo A, Faletti C, Masciocchi C. Musculoskeletal tumours: Preliminary experience with perfusion MRI. *Radiol Med* 2007; 112: 550-561.
22. Zoccali C, Rossi B, Zoccali G, Barbarino E, Gregori L, Barile A, Masciocchi C. A new technique for biopsy of soft tissue neoplasms: a preliminary experience using MRI to evaluate bleeding. *Minerva Med* 2015; 106: 117-20.
23. Masciocchi C, Barile A, Lelli S, Calvisi V. Magnetic resonance imaging (MRI) and arthro-MRI in the evaluation of the chondral pathology of the knee joint. *Radiol Med* 2004; 108: 149-58.
24. Masciocchi C, Zugaro L, Arrigoni F, Gravina GL, Mariani S, La Marra A, Zoccali C, Flamini S, Barile A. Radiofrequency ablation versus magnetic resonance guided focused ultrasound surgery for minimally invasive treatment of osteoid osteoma: a propensity score matching study. *Eur Radiol* 2016; 26: 2472-2481.
25. Masciocchi C, Conchiglia A, Gregori LM, Arrigoni F, Zugaro L, Barile A. Critical role of HIFU in musculoskeletal interventions. *Radiol Med* 2014; 119: 470-475.
26. Salvati F, Rossi F, Limbucci N, Pistoia ML, Barile A, Masciocchi C. Mucoïd metaplastic-degeneration of anterior cruciate ligament. *J Sports Med Phys Fitness* 2008; 48: 483-487.
27. Barile A, Lanni G, Conti L, Mariani S, Calvisi V, Castagna A, Rossi F, Masciocchi C. Lesions of the biceps pulley as cause of anterosuperior impingement of the shoulder in the athlete: Potentials and limits of MR arthrography compared with arthroscopy. *Radiol Med* 2013; 118: 112-122.
28. Di Cesare E, Gennarelli A, Di Sibio A, Felli V, Splendiani A, Gravina GL, Barile A, Masciocchi C. Assessment of dose exposure and image quality in coronary angiography performed by 640-slice CT: a comparison between adaptive iterative and filtered back-projection algorithm by propensity analysis. *Radiol Med* 2014; 119: 642-649.
29. Di Cesare E, Splendiani A, Barile A, Squillaci E, Di Cesare A, Brunese L, Masciocchi C. CT and MR imaging of the thoracic aorta. *Open Med* 2016; 11: 143-151.
30. Ierardi AM, Xhepa G, Piffaretti G, Bacuzzi A, Tozzi M, Carbone M, Barile A, Squillaci E, Fonio P, Brunese L, Carrafiello G. Clinical experience with Angiojet: A comprehensive review. *Int. Angiol* 2015; 34: 1-14.
31. Reginelli A, Capasso R, Ciccone V, Croce MR, Di Grezia G, Carbone M, Maggioletti N, Barile A, Fonio P, Scialpi M, Brunese L. Usefulness of triphasic CT aortic angiography in acute and surveillance: Our experience in the assessment

- of acute aortic dissection and endoleak. *Int J Surg* 2016; 33: S76-S84.
32. de Filippo M, Azzali E, Pesce A, Saba L, Mostardi M, Borgia D, Barile A, Capasso R, de Palmi F, Caravaggio F. CT arthrography for evaluation of autologous chondrocyte and chondral-inductor scaffold implantation in the osteochondral lesions of the talus. *Acta Biomedica* 2016; 87: 51-56.
33. Giordano AV, Arrigoni F, Bruno F, Carducci S, Varrassi M, Zugaro L, Barile A, Masciocchi C. Interventional Radiology Management of a Ruptured Lumbar Artery Pseudoaneurysm after Cryoablation and Vertebroplasty of a Lumbar Metastasis. *Cardiovasc Intervent Radiol* 2017; 40: 776-779.
34. Floridi C, Reginelli A, Capasso R, Fumarola E, Pesapane F, Barile A, Zappia M, Caranci F, Brunese L. Percutaneous needle biopsy of mediastinal masses under C-arm conebeam CT guidance: diagnostic performance and safety. *Med Oncol* 2017; 34:
35. Nurzynska D, DiMeglio F, Castaldo C, Latino F, Romano V, Miraglia R, Guerra G, Brunese L, Montagnani S. Flat-foot in children: Anatomy of decision making. *Ital J Anat Embryol* 2012; 117: 98-106.
36. Masciocchi C, Conti L, D'Orazio F, Conchiglia A, Lanni G, Barile A, Errors in musculoskeletal MRI, Errors in Radiology, Springer-Verlag Milan 2012, pp. 209-217.
37. Caranci F, Tedeschi E, Leone G, Reginelli A, Gatta G, Pinto A, Squillaci E, Briganti F, Brunese L. Errors in neuroradiology. *Radiol Med* 2015; 120: 795-801.
38. Caranci F, Briganti F, La Porta M, Antinolfi G, Cesarano E, Fonio P, Brunese L, Coppolino F. Magnetic resonance imaging in brachial plexus injury. *Musculoskeletal Surg* 2013; 97: S181-S190.
39. Masala S, Nano G, Marcia S, Muto M, Fucci FPM, Simonetti G. Osteoporotic vertebral compression fractures augmentation by injectable partly resorbable ceramic bone substitute (Cerament™|SPINE SUPPORT): A prospective nonrandomized study. *Neuroradiology* 2012; 54: 589-596.
40. Guarnieri G, Vassallo P, Pezzullo MG, Laghi F, Zeccolini F, Ambrosiano G, Galasso R, Muto M, Izzo R. A comparison of minimally invasive techniques in percutaneous treatment of lumbar herniated discs a review. *Neuroradiol J* 2009; 22: 108-121.
41. Miele V, Di Giampietro I, Ianniello S, Pinto F, Trinci M. Diagnostic imaging in pediatric polytrauma management. *Radiol Med* 2014; 120: 33-49.
42. Menichini G, Sessa B, Trinci M, Galluzzo M, Miele V. Accuracy of contrast-enhanced ultrasound (CEUS) in the identification and characterization of traumatic solid organ lesions in children: a retrospective comparison with baseline US and CE-MDCT. *Radiol Med* 2015; 120: 989-1001.
43. Zappia M, Carfora M, Romano AM, Reginelli A, Brunese L, Rotondo A, Castagna A. Sonography of chondral print on humeral head. *Skelet Radiol* 2016; 45: 35-40.
44. Muto M, Perrotta V, Guarnieri G, Lavanga A, Vassallo P, Reginelli R, Rotondo A. Vertebroplasty and kyphoplasty: Friends or foes? *Radiol Med* 2008; 113: 1171-1184.
45. Filippou G, Adinolfi A, Cimmino MA, Scire CA, Carta S, Lorenzini S, Santoro P, Sconfienza LM, Bertoldi I, Picerno V, Di Sabatino V, Ferrata P, Galeazzi M, Frediani B. Diagnostic accuracy of ultrasound, conventional radiography and synovial fluid analysis in the diagnosis of calcium pyrophosphate dihydrate crystal deposition disease. *Clin Exp Rheumatol* 2016; 34: 254-60.
46. Al Hares G, Eschweiler J, Radermacher K. Combined magnetic resonance imaging approach for the assessment of in vivo knee joint kinematics under full weight-bearing conditions. *Proc Inst Mech Eng H* 2015; 229: 439-51.
47. Nicholson JA, Sutherland AG, Smith FW, Kawasaki T. Upright MRI in kinematic assessment of the ACL-deficient knee. *Knee* 2012; 19: 41-8.
48. Nicholson JA, Sutherland AG, Smith FW. Single bundle anterior cruciate reconstruction does not restore normal knee kinematics at six months: an upright MRI study. *J Bone Joint Surg Br* 2011; 93: 1334-40.
49. Besier TF, Draper CE, Gold GE, Beaupre GS, Delp SL. Patellofemoral joint contact area increases with knee flexion and weight-bearing. *J Orthop Res* 2005; 23: 345-50.
50. Barile A, Conti L, Lanni G, Calvisi V, Masciocchi C. Evaluation of medial meniscus tears and meniscal stability: Weight-bearing MRI vs arthroscopy. *Eur J Radiol* 2013; 82: 633-639.
51. Ferrero G, Fabbro E, Orlandi D, Martini C, Lacelli F, Serafini G, Silvestri E, Sconfienza LM. Ultrasound-guided injection of platelet-rich plasma in chronic Achilles and patellar tendinopathy. *J Ultrasound* 2012; 15: 260-6.
52. Klauser AS, Tagliafico A, Allen GM, Boutry N, Campbell R, Court-Payen M, Grainger A, Guerini H, McNally E, O'Connor PJ, Ostlere S, Petroons P, Reijnierse M, Sconfienza LM, Silvestri E, Wilson DJ, Martinoli C. Clinical indications for musculoskeletal ultrasound: a Delphi-based consensus paper of the European Society of Musculoskeletal Radiology. *Eur Radiol* 2012; 22: 1140-8.
53. Noehren B, Barrance PJ, Pohl MP, Davis IS. A comparison of tibiofemoral and patellofemoral alignment during a neutral and valgus single leg squat: an MRI study. *Knee* 2012; 19: 380-6.
54. Barrance PJ, Gade V, Allen J, Cole JL. American Society of Biomechanics Clinical Biomechanics Award 2013: tibiofemoral contact location changes associated with lateral heel wedging--a weight bearing MRI study. *Clin Biomech (Bristol, Avon)* 2014; 29: 997-1002.
55. Lustig S, Scholes CJ, Balestro JC, Parker DA. In vivo assessment of weight-bearing knee flexion reveals compartment-specific alterations in meniscal slope. *Arthroscopy* 2013; 29: 1653-60.
56. Bruno F, Smaldone F, Varrassi M, Arrigoni F, Barile A, Di Cesare E, Masciocchi C, Splendiani A. MRI findings in lumbar spine following O2-O3 chemiodiscolysis: A long-term follow-up. *Interv Neuroradiol* 2017; 23: 444-450.
57. Splendiani A, D'Orazio F, Patriarca L, Arrigoni F, Caranci F, Fonio P, Brunese L, Barile A, Di Cesare E, Masciocchi C. Imaging of post-operative spine in intervertebral disc pathology. *Musculoskeletal Surg* 2017; 101: 75-84.

58. Patriarca L, Letteriello M, Di Cesare E, Barile A, Gallucci M, Splendiani A. Does evaluator experience have an impact on the diagnosis of lumbar spine instability in dynamic MRI? Interobserver agreement study. *Neuroradiol J* 2015; 28: 341-346.
59. Splendiani A, Perri M, Grattacaso G, Di Tunno V, Marsicano C, Panebianco L, Gennarelli A, Felli V, Varrassi M, Barile A, Di Cesare E, Masciocchi C, Gallucci M. Magnetic resonance imaging (MRI) of the lumbar spine with dedicated G-scan machine in the upright position: a retrospective study and our experience in 10 years with 4305 patients. *Radiol Med* 2016; 121: 38-44.
60. Splendiani A, Ferrari F, Barile A, Masciocchi C, Gallucci M. Occult neural foraminal stenosis caused by association between disc degeneration and facet joint osteoarthritis: Demonstration with dedicated upright MRI system. *Radiol Med* 2014; 119: 164-174.
61. Aliprandi A, Sconfienza LM, Randelli P, Bandirali M, Tritella S, Di Leo G, Sardanelli F. Magnetic resonance imaging of the knee after medial unicompartmental arthroplasty. *Eur J Radiol* 2011; 80: e416-21.
62. Dahabreh IJ, Hadar N, Chung M. Emerging magnetic resonance imaging technologies for musculoskeletal imaging under loading stress: scope of the literature. *Ann Intern Med* 2011; 155: 616-24.
63. Reginelli A, Russo A, Maresca D, Martiniello C, Capabianca S, Brunese L. Imaging Assessment of Gunshot Wounds. *Semin. Ultrasound CT MRI* 2015; 36: 57-66.
64. Muto M. MR Imaging of the Spine: Where Are We Now? *Magn Reson Imaging Clin North Am* 2016; 24: xiii-xiv.
65. Grassi R, Lombardi G, Reginelli A, Capasso F, Romano F, Floriani I, Colacurci N. Coccygeal movement: assessment with dynamic MRI. *Eur J Radiol* 2007; 61: 473-9.
66. Draganich LF, Andriacchi TP, Andersson GB. Interaction between intrinsic knee mechanics and the knee extensor mechanism. *J Orthop Res* 1987; 5: 539-47.
67. Dragoo JL, Phillips C, Schmidt JD, Scanlan SF, Blazek K, Steadman JR, Williams A. Mechanics of the anterior interval of the knee using open dynamic MRI. *Clin Biomech (Bristol, Avon)* 2010; 25: 433-7.
68. Mariani S, La Marra A, Arrigoni F, Necozone S, Splendiani A, Di Cesare E, Barile A, Masciocchi C. Dynamic measurement of patello-femoral joint alignment using weight-bearing magnetic resonance imaging (WB-MRI). *Eur J Radiol* 2015; 84: 2571-2578.
69. Draper CE, Besier TF, Fredericson M, Santos JM, Beaupre GS, Delp SL, Gold GE. Differences in patellofemoral kinematics between weight-bearing and non-weight-bearing conditions in patients with patellofemoral pain. *J Orthop Res* 2011; 29: 312-7.
70. Pal S, Besier TF, Beaupre GS, Fredericson M, Delp SL, Gold GE. Patellar maltracking is prevalent among patellofemoral pain subjects with patella alta: an upright, weight-bearing MRI study. *J Orthop Res* 2013; 31: 448-57.
71. Becher C, Fleischer B, Rase M, Schumacher T, Ettinger M, Ostermeier S, Smith T. Effects of upright weight bearing and the knee flexion angle on patellofemoral indices using magnetic resonance imaging in patients with patellofemoral instability. *Knee Surg Sports Traumatol Arthrosc* 2017; 25: 2405-2413.
72. Izadpanah K, Weitzel E, Vicari M, Hennig J, Weigel M, Sudkamp NP, Niemeier P. Influence of knee flexion angle and weight bearing on the Tibial Tuberosity-Trochlear Groove (TTTG) distance for evaluation of patellofemoral alignment. *Knee Surg Sports Traumatol Arthrosc* 2014; 22: 2655-61.
73. Callaghan MJ, Guney H, Reeves ND, Bailey D, Doslikova K, Maganaris CN, Hodgson R, Felson DT. A knee brace alters patella position in patellofemoral osteoarthritis: a study using weight bearing magnetic resonance imaging. *Osteoarthritis Cartilage* 2016; 24: 2055-2060.
74. Liodakis E, Kenaway M, Doxastaki I, Krettek C, Haasper C, Hankemeier S. Upright MRI measurement of mechanical axis and frontal plane alignment as a new technique: a comparative study with weight bearing full length radiographs. *Skeletal Radiol* 2011; 40: 885-9.
75. Gade V, Allen J, Cole JL, Barrance PJ. Upright Magnetic Resonance Imaging Tasks in the Knee Osteoarthritis Population: Relationships Between Knee Flexion Angle, Self-Reported Pain, and Performance. *Arch Phys Med Rehabil* 2016; 97: 1107-14.

Received: 15 September 2017

Accepted: 20 December 2017

Correspondence:

Federico Bruno M.D.

Department of Biothecology and Applied Clinical Sciences, University of L'Aquila

MRI Unit - S. Salvatore Hospital Vetoio Street - 67100, L'Aquila, Italy

Tel. +390862414258

Fax +39.0862.311277

E-mail: federico.bruno.1988@gmail.com