

Residual interfragmentary gap after intramedullary nailing of fragility fractures of the humeral diaphysis: short and midterm term results

Fabrizio Ferrara, Elena Biancardi, Georgios Touloupakis, Luigi Bibiano, Stefano Ghirardelli, Guido Antonini, Cornelio Crippa

Department of Orthopedics and Traumatology, San Carlo Borromeo Hospital, Milan, Italy

Summary. The purpose of this retrospective study was to evaluate the short and midterm radiological outcome with regards to bone healing, correlated with humeral shaft fractures treated with anterograde intramedullary nailing, when interfragmentary gap was significant. Here, we critically review our experience of short and midterm term results in over 65 year-old patients. Inclusion criteria in the study were: (1) patients over 65 years old (2) patients with displaced humeral mid shaft fractures (AO/OTA 12 A B C type fractures); (3) patients treated with closed reduction and internal fixation with intramedullary nail (Trigen Humeral Nail® Smith & Nephew) with at least two screws for proximal locking and one screw for distal locking; (4) residual interfragmentary gap, being considered significant any gap >6 mm (being 7 mm the minimum nail diameter available in our facility). Various factors were considered in our analysis: the size of the interfragmentary gap in both projections (also the mean of the measured gaps was calculated), the relationship between the greater and the mean interfragmentary gap and the second diameter measurement of the nail in the half distal part, the number of the screws in distal locking procedure, the use of a reaming procedure or not, the AO classification, the actual age at the time of surgery, the operating time, the nail second diameter as described before and its ratio with the measured residual gap. At 3 months follow-up, 4 patients showed radiographic healing (26,67%), 9 patients showed a visible callus (60%), with a total of 13 patients (86,67%) showing signs of normal recovery, the remaining 2 patient had insufficient callus formation (13,3%). At 6 months follow-up, 1 patient was missing (6,67%), although radiographic healing was already evident during the previous follow-up check, another one showed incomplete callus formation, the remaining 13 patients showed radiographic healing (86,67%), with a total of 14 patient considered healed at 6 months follow-up (93,33%). In conclusion, osteosynthesis with anterograde nail in geriatric patients appears to be a quite safe approach despite a great interfragmentary gap. After 6 months of treatment, callus formation and the overall clinical outcome were proven to be above satisfaction. (www.actabiomedica.it)

Key words: interlocking nail, humeral shaft fractures, interfragmentary gap

Introduction

There is no consensus among physicians on the best approach to treat humeral shaft fractures in the elderly; at present, all proposed treatments are recommended, but a gold standard method has not been

developed yet. Several non-surgical procedures such as functional bracing, as well as surgical methods like anterograde and retrograde intramedullary nailing, plating or external fixation are frequently used for the treatment of these fractures (1). Nevertheless, none of these approaches is complication-free; in fact, many

technical circumstances like comminution, open fracture and unstable fixation can woefully lead to a fixation failure. Ultimately, in geriatric patients, the goal of treatment is a quick comeback to the daily activities.

Several recent studies report that the treatment of humerus shaft fractures with locked antegrade intramedullary nailing provides enough fixation and possibility of early movement of the shoulder and elbow joints. This approach is typically coupled with satisfactory radiological and functional results (2). It is broadly claimed that humeral nailing should provide a kind of fixation that restores length, alignment, and rotation of the humeral shaft fractures. Nevertheless, a real functional reduction by nailing is usually demanding and it is very common that a residual fracture gap, due to distraction in the fracture site, does not allow for a satisfactory radiological outcome. Unfortunately, many orthopedic surgeons deal with intramedullary humeral nailing without focusing to anatomic reduction of the fragments, an event that usually affects functional recovery.

The aim of this retrospective study was to evaluate the short and midterm radiological outcomes, with regards to bone healing, in humeral shaft fractures treated with antegrade intramedullary nailing, in the presence of an important interfragmentary gap. We therefore report our experience as well as the short and midterm results in over 65-year-old patients.

Patients and Methods

We retrospectively evaluated the outcomes in patients with a fragility fracture of the humeral shaft, treated at San Carlo Borromeo Hospital (Milan, Italy) from November 2012 until May 2017. An informed consent regarding the use of clinical data for scientific publication was obtained. The humeral shaft fractures in this study were identified according to the AO classification. According to the National Osteoporosis Foundation, any fracture resulting from a fall from a standing height or less is considered a fragility fracture. This is typically associated with low bone mineral density or established osteoporosis, and it is common in elderly patients.

The patient inclusion criteria in this study were the following:

(1) age ≥ 65 years (2) diagnosis of displaced humeral mid shaft fractures (AO/OTA 12 A B C type fractures); (3) patients treated with closed reduction and internal fixation with intramedullary nail (Trigen Humeral Nail® Smith & Nephew), with at least two screws for proximal locking and one screw for distal locking;

to note, this type of nail (Trigen Humeral Nail® Smith & Nephew) present a difference in diameter between the proximal (epiphyseal) section and the distal (diaphyseal) one, the second being smaller than the former: in the present article, any reference to a nail diameter is meant to be referred to the distal diameter. (4) presence of a residual interfragmentary gap > 6 mm of diameter (being 7 mm the minimum distal nail diameter measurement available in our facility).

The patient exclusion criteria were the following:

(1) Comorbidity Severity Score (ASA) ≥ 4 ; (2) a post-operative follow-up shorter than 6 months; (3) the presence of articular fractures or fractures that involved the humeral head; (4) open fractures; (5) isolated transverse fractures of humeral shaft (AO/OTA A3).

X-ray images of all the eligible patients were obtained from the Picture Archiving and Communication System (PACS) sited in our Institute. The images were obtained at three different views (anteroposterior, intra or extra and rotation views) immediately after osteosynthesis, and in at least two standard projections (anteroposterior and lateral views) at follow-up.

The surgical technique consisted of a synthesis with an antegrade Trigen nail (S&N). All patients were placed in supine position on a radiolucent table. Cephazoline (2 g) was administered 30 minutes prior to skin incision for infection prophylaxis. A proximal anterolateral trans-deltoid surgical access was used: a small skin incision was performed from the anterolateral edge of the acromion distally towards the deltoid insertion; subsequently, the deltoid muscle fibers were retracted, and the supraspinatus tendon was longitudinally incised for 1 cm and sutured at the end of the procedure to minimize the damage of the rotator cuff. The nail's entry point was medial to the greater tuberosity of the proximal humerus. After the insertion of a guide wire through the opening made in the supraspinatus tendon, the surgeon proceeded to indirect reduction of the fracture.

Multiple controls under image intensifier were necessary. Several nail diameters were used. Two or three screws were used for proximal locking. A single or double screw distal locking was performed with the Sureshot System (S&N®). A single arm sling was positioned to all patients lasting for two weeks after surgery. Assisted mobilization of the shoulder was recommended to each patient.

All patients were followed up as outpatients with X-ray control scans according to our protocol (AP, intra, extra and rotation projection of the humerus) after 40 days, 3 months, and 6 months, and thereafter at regular intervals depending on the progress of fracture healing. After each follow-up, proof of the clinical examination was obtained. When available, clinical data were also recorded through the hospital database.

Bone union and complications such as pseudarthrosis, infections and nerve lesions were evaluated in the immediate post-operative period. In addition, correct function of the rotator cuff tear was also evaluated.

Bone healing and relative complications, such as the presence of a radiopaque callus in the interfragmentary gap, were recorded in every patient in at least one of the three projections at 3 and 6 months of follow-up.

The bone callus already formed at the fracture site was observed at 3 and 6 months of follow-up and compared to the previous postoperative x-rays. A single scale for measure of callus formation was used (insufficient, visible and advanced) and clinical data were simplified for statistical use (very limited function, limited function, good function, excellent function). Several factors were considered in our analysis: the size of the interfragmentary gap in both projections (the mean of the measured gaps was also calculated), the relationship between both the maximum and the mean interfragmentary gap values and the nail diameter, the number of screws used during the distal locking procedure, the use of a reaming procedure or not, the AO classification, the patient's age at the time of surgery, the surgical procedure length, the nail diameter and its ratio with the measured residual gap.

The radiological and clinical outcomes, as well as the presence or absence of complications in the short and midterm periods were evaluated in relationship with the aforementioned factors.

Results

The cohort of our patients that met the inclusion criteria was composed of 22 subjects. There were 17 female and 5 male patients with a mean age of 76,2 (± 7) years (range: 65-88 years). The AO classification was used to categorize the fractures (Table 1): A1, 8 cases; B1, 6 cases; B2, 4 cases; B3, 2 cases; C1, 2 cases.

The mean surgery time was 88 ($\pm 25,7$) minutes (range: 50 - 140 min).

Two or three proximal screws were used for proximal locking (13 patients with 2 screws, 9 patients with 3 screws); single or double-screw distal locking was performed with the Sureshot System (S&N®): 15 patients receiving one screw, 7 patients receiving two screws. The diameter of the nail used was 7 mm in 16 patients, 7.5 and 8.5 mm in 3 patients for each nail diameter, respectively.

A reaming technique was performed in 13 patients (59,1%), while the remaining 9 were treated with a non-reaming technique. No intra-operative or other major complications were observed, like non-unions, nerve lesions or infection. We reported only

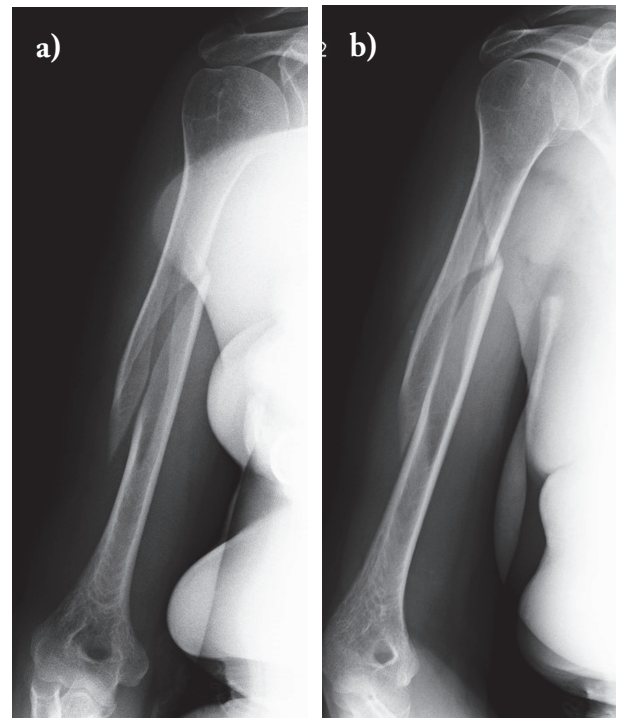


Figure 1 a, b. Female patient, 78 years old, 12B1 type humeral fracture according to the AO/OTA classification

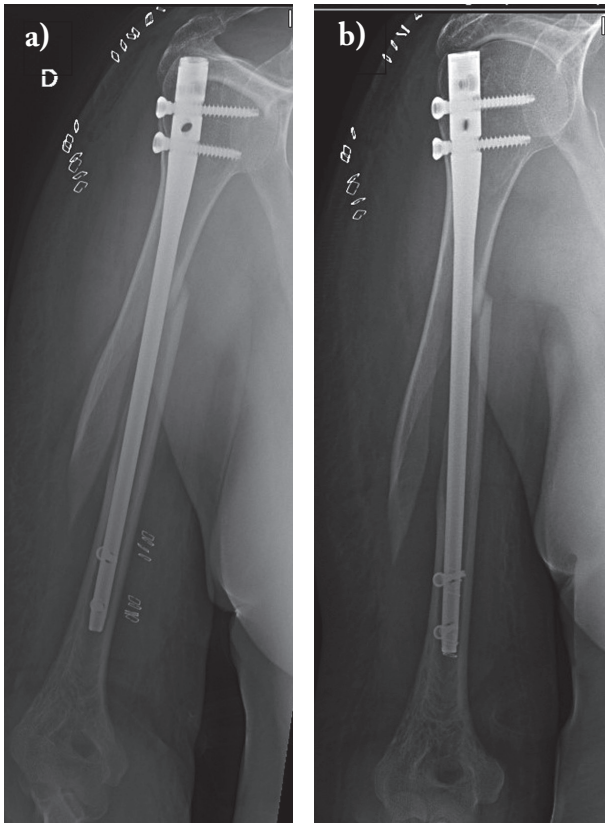


Figure 2 a, b. Post-operative images, a 7 mm diameter of Trigen S&N nail was used with 2 distal locking screws and 2 proximal screws. Interfragmentary gap is 1,46 cm in figure 2a and 1,7 cm in figure 2b

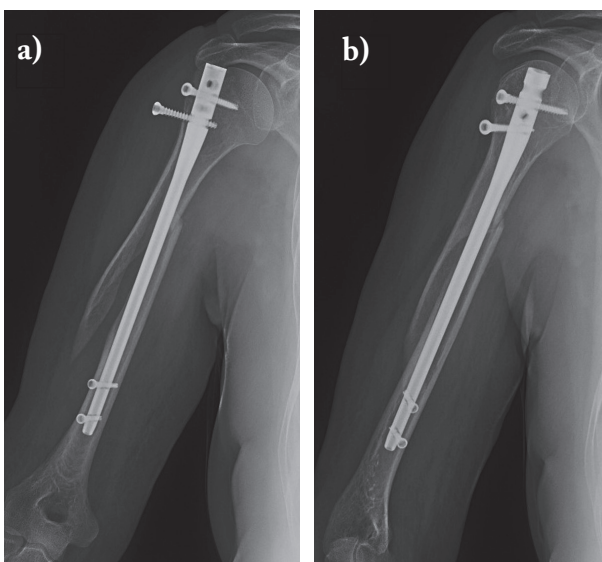


Figure 3 a, b. X-rays one month after surgery. No signs of bone callus. Mobilization of one of the proximal screws

a complication that could be related to the surgical procedure: a patient reported a rotator cuff tear documented by MRI three months after surgery. In another patient, the proximal screw was removed after one month because of screw loosening. No other complications were observed. Regarding residual post-reduction gaps, the mean value of the intra-rotation gap was 0,97 (\pm 0,53) mm, the mean extra-rotation gap was 0,89 (\pm 0,55) mm, and the overall mean gap was 0,93 (\pm 0,49) mm, the maximum mean gap measured in both projections was 1,07 (\pm 0,49) mm. The ratio between gap and nail diameter values was also measured, being 1,27 (\pm 0,67) when considering the mean gap value, and 1,47 (\pm 0,67) when considering the maximum gap value.

Seven patients did not present themselves at follow-up; hence, the radiographic results are related to only 15 patients ($n=15$). The X-ray images obtained at 6 months of follow-up were missing for one of them. However, the patient was not excluded since the 3 month-x-rays showed complete healing.

At 3 months of follow-up, 4 patients showed radiographic healing (26,67%), 9 patients showed a visible callus (60%), 2 patients showed insufficient callus formation (13,3 %). Overall, a total of 13 patients showed radiographic signs of recovery (86,67%).

At 6 months of follow-up, 1 patient's images were missing although radiographic healing was already evident during the previous follow-up check, 1 patient showed incomplete callus formation (6,67%), the remaining 13 patients showed radiographic healing (86,67%), with a total of 14 patient considered healed radiographically at 6 months of follow-up (93,33%).

Regarding clinical data, at 3 months of follow-up, 1 patient showed very limited function (6,67%), limited function was seen in 7 cases (46,67%), good function in 5 patients (33,33%), excellent function in 1 patient, while data for the remaining patient were missing; therefore, a total of 40 % showed clinical acceptable results.

At 6 months, clinical data from 2 patients (13,3%) were missing, function was reported as very limited in 1 patient (6,67 %), limited in 1 patient, excellent in 2 patients (13,3%) and good in 7 patients (46,67%), with a total of 11 patients (73,3%) showing acceptable clinical results.

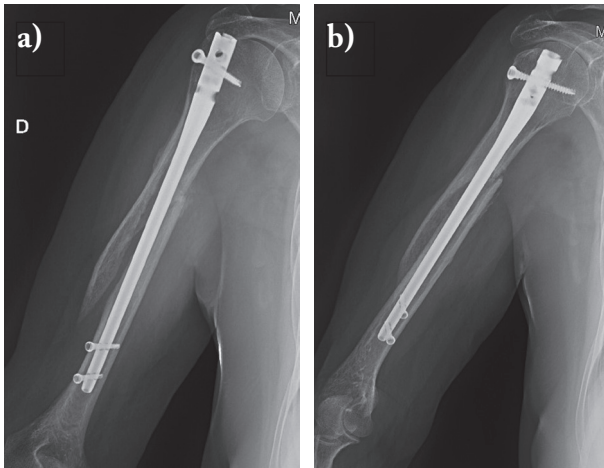


Figure 4 a, b. X-rays 3 months after surgery: despite of the initial gap, bone callus is already visible. The mobilized screw has been removed

Statistical analysis was performed to identify factors able to influence clinical prognosis. When applicable, the chi-square test was used to compare clinical and radiographic results, as well as the presence or absence of complications, analyzing categorical variables (AO classification, nail diameter, number of screws, reaming). If the chi-square requirements were not met, Fisher exact test was used, by converting the outcome index in nominal variables (acceptable vs not acceptable result). Age and length of surgery were compared by a Kruskal-Wallis test to study the effect of the reduction gap in the outcomes.

None of the categorical factors considered was correlated with a difference in x-ray or clinical follow-up at 3 months. Only one patient did not radiographically show complete healing after 6 months, therefore no statistical analysis could be performed in that case. Similarly, clinical results at 3 and 6 months were not influenced by any one of the factors considered; also, no factor was detected as related to the onset of complications.

Analyzing parameters such as age, length of surgery and gap measurement, no statistically significant differences were found in terms of clinical outcome at 3 and 6 months of follow-up. Moreover, there were no significant differences in age and length of surgery in the various outcome groups at radiographical follow-up at the same time points. Only the quality of reduction, namely the gap measurement, showed a signifi-

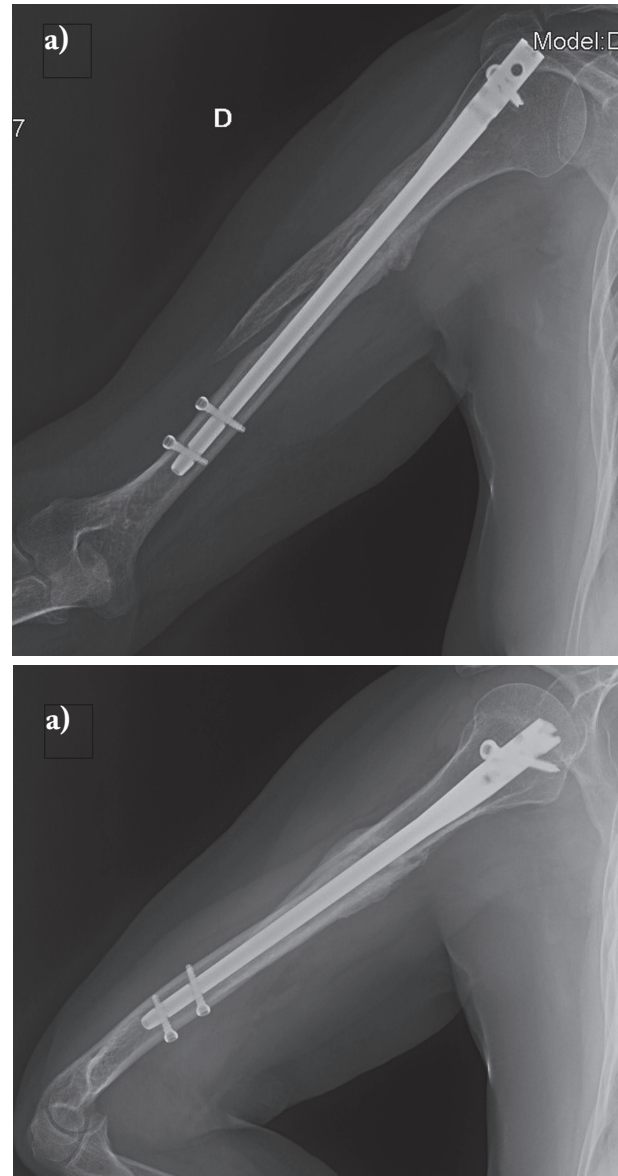
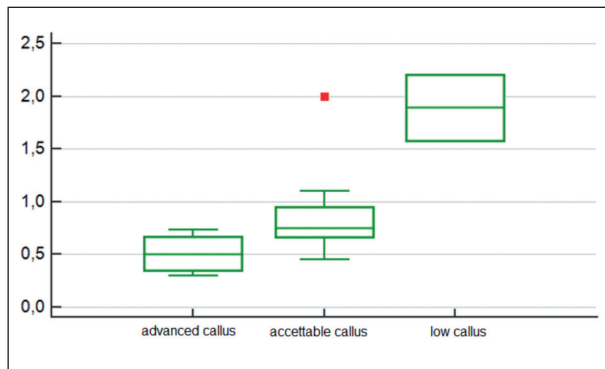


Figure 5 a, b. X-rays 6 months after surgery: the bone callus is visible with clear signs of fracture healing

cant difference at 3 months of radiographic follow-up between patients with different outcomes: patients with less callus formation showed significantly higher gap as the median of the gaps was 0,5 cm in patients with advanced callus formation versus 1,89 cm in patients with low callus formation ($p < 0,005$), as shown in Graph 1. Remarkably this difference disappeared at 6 months of follow-up, since almost all patients were healed. To note, this difference was significant only



Graph 1. The following graph represents interfragmentary gap values (Y axis) related to callus formation at 3 months follow-up (X axis). The red dot is an outlier. The significantly lower callus formation is clearly shown in patients with bigger post-operative gaps

when considering the mean gap value, and not using the maximum gap value. Moreover, no differences in the influence on the outcomes were shown when calculating the gap as a ratio with nail diameter, being only the 3-month radiographic follow-up significantly influenced by the variable.

Discussion and Conclusion

Despite functional brace treatment being the gold standard in the conservative treatment of humerus shaft fractures, intramedullary nailing is the most common surgical method of fixation. Surgical treatment significantly decreases the risk of bad union and non-union, which are the most important complications of the conservative treatment (3).

Many authors consider plate fixation with open reduction or the Minimally Invasive Plate Osteosynthesis (MIPO) technique as the most appropriate methods of surgical treatment, but they are technically more demanding (4, 5). Compared to these two approaches, the intramedullary nailing is a faster procedure and could be more applicable in geriatric patients. Intramedullary fixation has the advantage to act as a load-sharing device and to preserve the periosteal blood supply around the fracture, so as to allow healing.

Decreased rotator cuff function after anterograde nailing of the humerus has been thought to be the

cause of painful and decreased motion of the shoulder joint in active patients, providing an overall unsatisfactory functional result. The surgical technique has been cited as the main reason for rotator cuff dysfunction in young patients; however, in over 65-year old patients, if a proper surgical technique is practiced, the risk of rotator cuff tear is reduced, and satisfactory functional outcome scores can be expected in the post-operative period after intramedullary nailing for humeral shaft fractures (6).

In our study, we did not make a comparative study, for example between intramedullary nail and locking compression plate, as our findings (93,33 % of radiological healing and 73,3 % of acceptable clinical results at 6 months follow-up) were more than satisfactory.

Rommens et al. recommend avoiding diastases in the fracture gap, closing it by manual compression or through a compression device before static interlocking (7). Watson and Sanders claim that, after nail placement, there is often a distraction of the construct; according to them, this often leads to a non-union (8). Baltov et al. found a significant positive correlation between humeral shaft fractures locked in distraction and the risk of non-union. In fact, in their retrospective study they evaluated 111 patients with humeral shaft fracture treated with an intramedullary nail. They reported fracture distraction in 12,6% of the cases, in some of them greater than 4 mm (4,5%). Also, 2,7% of their patients showed delayed healing and 1,8% presented non-union (9).

In our retrospective study, we evaluated only geriatric patients with an interfragmentary gap >6 mm.

After intramedullary nailing in 22 patients, we measured an average postoperative fracture distraction of 1 cm. For many authors this may not be acceptable, but we found no difference in the outcome 6 months after surgery: indeed, from a radiological point of view, callus formation was slower in fractures with a bad reduction, and faster when a good reduction was achieved. However, from a clinical point of view, 73,3% of patients showed acceptable results, despite the radiological findings. In our study, clinical results were not influenced by factors such as the age of the patient, the length of the surgical procedure, the diameter of the intramedullary nail as well as the interfragmentary gap >6 mm. In fact, patients with greater distraction in

the fracture site showed less callus formation 3 months after surgery, but almost all patients showed acceptable callus formation at the 6 months follow-up. Only one patient out of 22 did not show radiological healing after 6 months.

A limit of this study was the low numerosity, with only 22 patients included due to strict inclusion criteria (over 65 years patients with a displaced humeral mid shaft fracture, treated with closed reduction and internal fixation with a locked intramedullary nail, with interfragmentary gap after surgery >6 mm) to avoid biases as much as possible.

In conclusion, osteosynthesis with anterograde nail in geriatric patients appears to be a quite safe approach despite a great interfragmentary gap. After 6 months of treatment, callus formation and the overall clinical outcome were proven to be above satisfaction.

Conflict of interest: Each author declares that he or she has no commercial associations (e.g. consultancies, stock ownership, equity interest, patent/licensing arrangement etc.) that might pose a conflict of interest in connection with the submitted article

References

1. Updegrave GF, Mourad W, Abboud JA Humeral shaft fractures. *J Shoulder Elbow Surg* 2018 Apr; 27(4): e87-e97.
2. Sahu RL, Ranjan R, Lal A. Fracture union in closed interlocking nail in humeral shaft fractures. *Chin Med J (Engl)* 2015 Jun 5; 128(11): 1428-32.
3. Carroll EA, Schweppe M, Langfitt M, Miller AN, Halvorson JJ. Management of humeral shaft fractures. *J Am Acad Orthop Surg* 2012 Jul; 20(7): 423-33.
4. Zhao JG, Wang J, Meng XH, Zeng XT, Kan SL Surgical interventions to treat humerus shaft fractures: A network meta-analysis of randomized controlled trials. *PLoS One* 2017 Mar 23; 12(3): e0173634.
5. Kulkarni VS, Kulkarni MS, Kulkarni GS, Goyal V, Kulkarni MG. Comparison between antegrade intramedullary nailing (IMN), open reduction plate osteosynthesis (ORPO) and minimally invasive plate osteosynthesis (MIPO) in treatment of humerus diaphyseal fractures. *Injury*. 2017 Aug;48 Suppl 2:S8-S13.
6. Benegas E, Ferreira Neto AA, Gracitelli ME, Malavolta EA, Assunção JH, Prada Fde S, Bolliger Neto R, Mattar R Jr. Shoulder function after surgical treatment of displaced fractures of the humeral shaft: a randomized trial comparing antegrade intramedullary nailing with minimally invasive plate osteosynthesis. *J Shoulder Elbow Surg* 2014 Jun; 23(6): 767-74.
7. Rommens PM, Kuechle R, Bord T, Lewens T, Engelmann R, Blum J. Humeral nailing revisited. *Injury* 2008 Dec; 39(12): 1319-28.
8. Watson JT, Sanders RW. Controlled Compression Nailing for At Risk Humeral Shaft Fractures. *J Orthop Trauma* 2017 Jun;31 Suppl 6:S25-S28.
9. Baltov A, Mihail R, Dian E. Complications after interlocking intramedullary nailing of humeral shaft fractures. *Injury* 2014 Jan; 45 Suppl 1: S9-S15.

Received: 1 May 2018

Accepted: 14 September 2018

Correspondence:

Georgios Touloupakis, MD, Orthopaedic Consultant,
The Department of Orthopedics and Traumatology,
San Carlo Borromeo Hospital (Milan, Italy)
Via Don Bartolomeo Grazioli 24 - 20161, Milano
Tel. (+39)3495106291
E-mail: yorgostoulou@gmail.com