

## C A S E R E P O R T

# Bent femoral intramedullary nail: a case report and review of the literature

*Gianluca Canton, Bramir Hoxhaj, Roberto Fattori, Luigi Murena*

Orthopaedics and Traumatology Unit, Cattinara Hospital - ASUITS, Trieste, Italy

**Summary.** Intramedullary nailing is considered the gold standard technique for the treatment of femoral shaft fractures. A rare complication of this technique is nail bending after a new trauma. In these cases nail removal might be really challenging. The present paper provides a brief review of surgical techniques purposed in the literature for bent nail removal and describes a clinical case. ([www.actabiomedica.it](http://www.actabiomedica.it))

**Key words:** bent intramedullary nail, femoral shaft fracture, bent femoral nail, bent nail removal

## Introduction

Intramedullary nailing is considered the gold standard technique for the treatment of femoral shaft fractures (1). In rare cases, a second trauma to the femoral shaft might lead to nail bending, which may be associated to a new fracture or displacement of the primary unhealed fracture. A bent nail is more difficult to remove in comparison to a broken one, because of the impossibility to pass the straight proximal intramedullary canal. In these difficult cases key factors for treatment planning are the degree of angulation of the nail, the direction of the deformity, the location of the deformity, patient local and general conditions and surgeon experience. Since the rarity of the pathology there is no widely accepted algorithm for the removal of a bent femoral nail (2). On the other hand, some literature issues regarding technical aspects and treatment proposals can be retrieved. Furthermore, definitive treatment of the fracture after nail removal may still deserve a discussion. The present paper provides a brief review of surgical techniques purposed in the literature for bent nail removal and describes a clinical case.

## Bent nail removal: surgical techniques

Standard removal of a bent nail as a straight nail is described by different authors (2, 3). The advantage

of this surgery is soft tissue preservation and no need for special equipment. The feasibility of this technique depends on the stiffness of the nail and the degree of deformity. Therefore, indications for this technique are in case of 15-20° of nail deformity, thin titanium nails, simple fracture and anterolateral deformity. Different authors have reported this technique as successful (2, 3).

Patterson et al. described the technique of closed straightening using a perineal post as fulcrum associated with external maneuvers and internal removal without opening the fracture site for nail resection (4). However, this technique is difficult to perform in case of antero-posterior angulation. In this cases Haffernan et al. advised the use of F® (Synthes West Chester, PA) tool for manual reduction of long bones. On the other hand, in case of thick nails the excessive force required may produce soft tissue injury and secondary fractures (5). The site of deformity location too proximal or too distal requires higher forces for reduction and is more predisposed to iatrogenic injuries. Beck et al. reported a secondary fracture during attempts of deformity reduction in such a case (6).

The most commonly used technique is partial weakening at the apex of the deformity of the nail and manual straightening. Location of the apex of nail deformity is the key factor for this technique. In case of valgus deformity indeed exposure of the medially

oriented apex may be surgically risky and demanding (7, 8). Percutaneous partial weakening technique at the apex of nail deformity using a drill bit has also been described. This technique has the advantage of being soft tissue sparing while the disadvantage of difficult metal debris irrigation and fluoroscopy dependency (9).

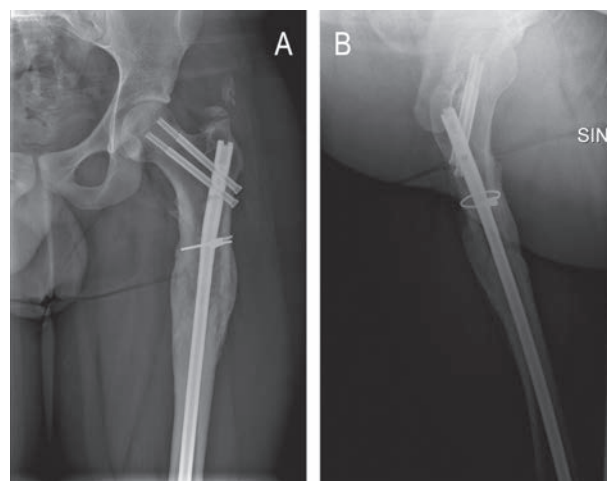
The total cutting at the deformity apex of the bent nail requires open technique and adequate instruments to cut the nail (10, 11). Total cutting of the nail and removal of the parts requires no force application for the reduction of the nail deformity thus reducing the risk of secondary fracture. This technique has the obvious disadvantage of greater soft tissues invasiveness while the advantage of low device demand and limited use of fluoroscopy. Furthermore, the use of continuous irrigation at the cutting site decreases the risk of tissue necrosis, nonunion and infection. The approach can be used both for nail cutting, anatomic bone reduction and fracture osteosynthesis as the apex of the deformity usually corresponds to the fracture site.

Cases when nail removal is not feasible even after nail cutting are reported in literature. In such cases the nail is usually stuck in the femoral canal, thus approach extension for longitudinal bone window opening should be considered as an option. A rectangular bone window and total nail exposure is necessary. The nail is extracted from this window in the proximal part and if not totally resected could be twisted for an easier extraction of the distal part of the nail. The bone window should then be fixed with cables or plate osteosynthesis. Nonetheless, wider soft tissue dissection to obtain an adequate bone window may lead to major complications (12). The main limitation of this technique is that in case of valgus deformity a medial femoral shaft approach might be necessary.

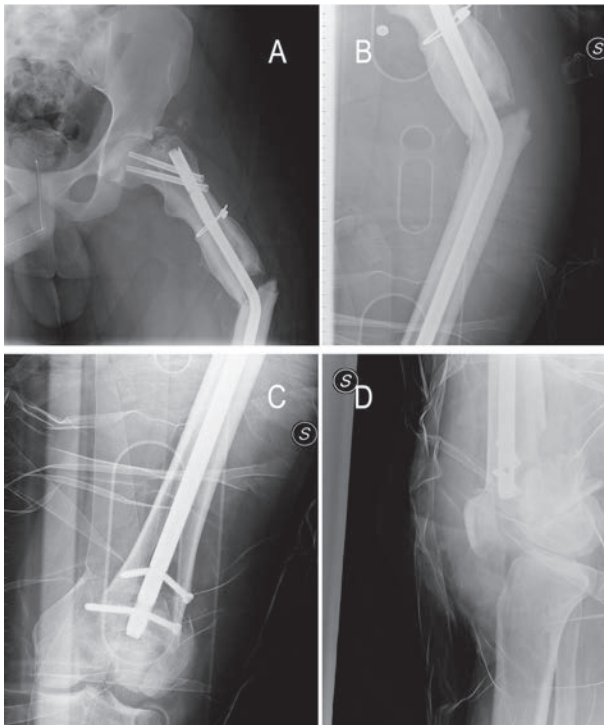
Another option for straightening the nail has been described using a broad plate and reduction clamps. The nail is straightened progressively using the forceps to gradually compress the shaft against the plate under fluoroscopy control (13). In cases of severe deformity and osteoporosis this technique should be used with caution due to high risk of secondary fracture. Successful application of this technique through a minimally invasive approach has been described by some authors (14).

## Case report

A 19 years old man was admitted to our hospital after a high energy motorcycle accident in February 2018. The patient presented with a severe varus deformity of the left thigh and an ipsilateral open fracture of the distal femur, without neurovascular injuries. Associated injuries were a left wrist trans-scaphoid trans-styloid perilunate fracture-dislocation and a right occipital condyle fracture. The patient height was 1,95 m and weight 115 kg. The patient had a previous motorcycle accident with a femoral diaphyseal fracture treated with an antegrade T2 Recon nail (Stryker™) almost 2 years before the recent trauma. Anamnestic data revealed full weight bearing without aids and full return to everyday life at the latest follow-up outpatient evaluation (18 months after surgery). However, the patient referred dull pain at the fracture site at weight bearing, with radiographic signs suspect for hypertrophic nonunion (Figure 1). Plain radiographs obtained at the emergency department showed a refracture of the femoral shaft in correspondence to the nonunion site with 145° nail angulation in the coronal plane. The distal locking screws were also bent (Figure 2). A comminuted fracture of the distal femur (AO type 33 C3) was confirmed, occurring at the tip of the previously implanted nail. The patient was treated in the first hours with a damage control procedure. An external fixator bridging



**Figure 1.** Eighteen months follow-up radiographs after intramedullary nailing for proximal third diaphyseal femur fracture, showing a possible hypertrophic nonunion A) AP view B) Lateral view

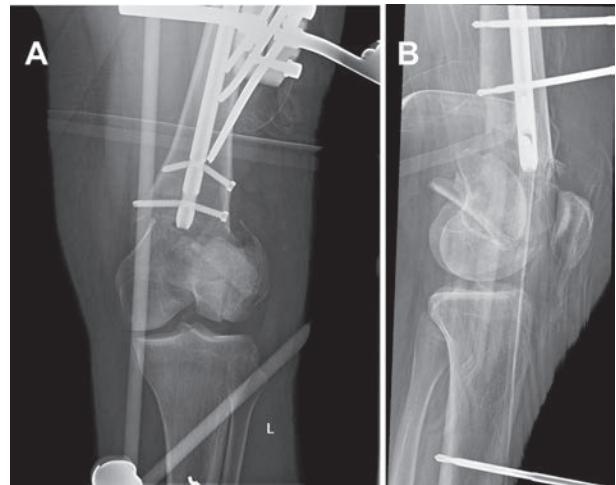


**Figure 2.** Plain radiographs obtained at the emergency department, showing a new fracture occurring at the nonunion site with 145° nail angulation in the coronal plane (A, B). A complex articular distal femur fracture was associated, with nail distal locking screws bending (C: AP view; D: Lateral view)

the knee joint was applied in order to gain length, axis and rotation at the distal femur fracture site (Figure 3). Accurate debridement of the open fracture was carried out, classifying the lesion as Gustilo (15) type II open fracture after the procedure. Primary closure of soft tissue was achieved. After surgery the patient was kept under observation for three days in intensive care unit and transferred to our orthopedics and traumatology unit afterwards. Definitive treatment was scheduled on the seventh day after trauma.

### Surgical technique

Under general anesthesia, the patient was positioned supine on the fracture table and previously implanted external fixator left in place. The injured limb was prepped and draped. Manual straightening of the nail was attempted under fluoroscopy control without success. Under fluoroscopy the apex of the bent



**Figure 3.** Post-operative radiographs of the distal femur showing fracture alignment after bridging external fixator application. A) AP view. B) Lateral view

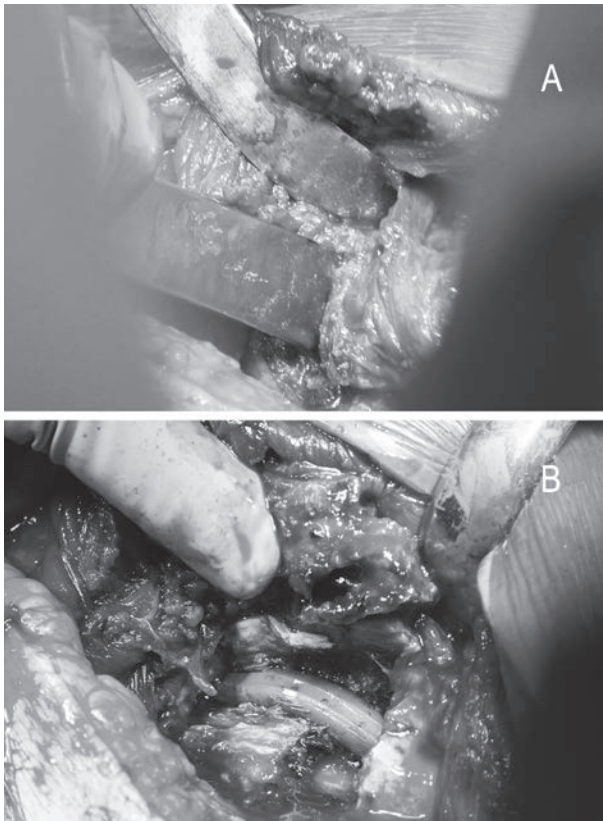
nail was identified. A limited lateral approach to the femur over the fracture deformity was performed. A small cortical bone window over the apex of the nail deformity was necessary to expose the nail for milling (Figure 4). The nail was resected with diamond burs until easy rupture was obtained at the apex of the deformity. Continuous irrigation and suction were used for tissue cooling and metal debris removal (Figure 5).

Lateral approach to the proximal femur was used for the removal of the proximal part of the ruptured nail after removal of the 2 cephalic blocking screws. The distal part was removed from the diaphyseal fracture site after removal of the distal blocking screws.

Under fluoroscopy the diaphyseal fracture was stabilized with stainless steel cerclage and definitively fixed with a 11x340 mm T2 Recon Stryker™ nail in static configuration. Two suction drainage were positioned during wound closure.

New sterile prepping and draping was used for the osteosynthesis of the complex articular distal femoral fracture after removal of the external fixator. Lateral approach to the distal femur was performed, with distal extension through a tibial tubercle osteotomy to obtain adequate exposure.

The fracture was reduced and definitively fixed with a Zimmer™ NCB distal femoral plate. Morcelized trabecular bone allograft was used to treat metaphyseal bone loss. The tibial tubercle was fixed with



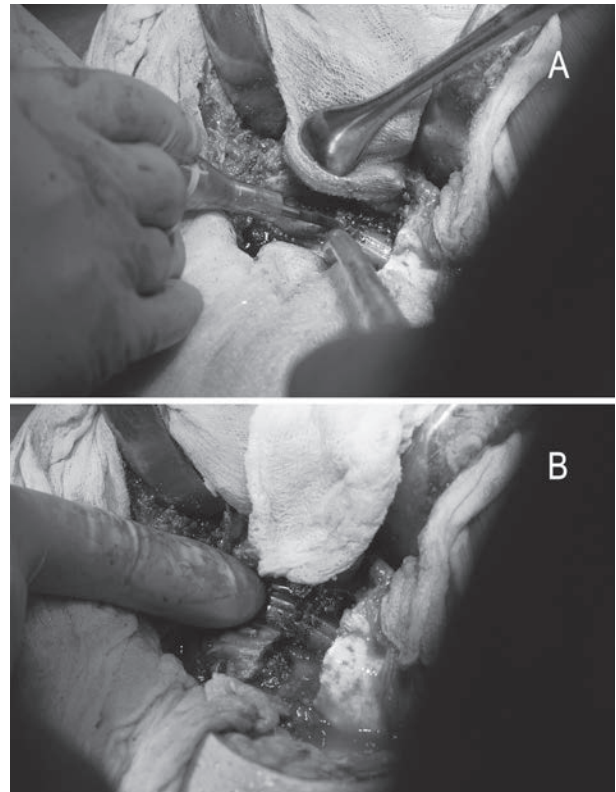
**Figure 4.** Intraoperative photographs. A) Apex of bone deformity is exposed after lateral access to the femur. A bone window on the fracture is being opened with an osteotome. B) Apex of the bent nail deformity is visible after bone window opening

2 3.5 mm cortical screws. A suction drainage was inserted during wound closure after abundant irrigation with saline solution.

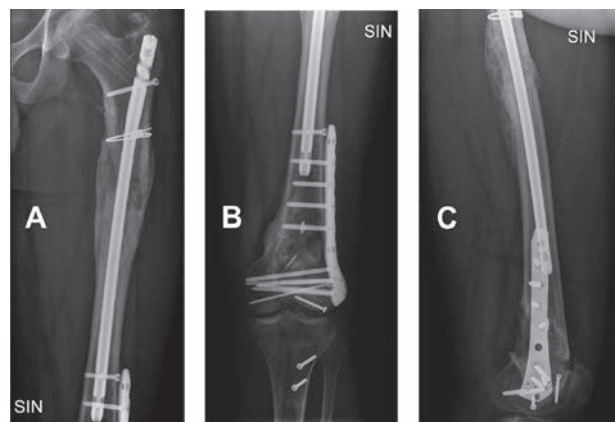
The post-operative rehabilitation protocol allowed immediate passive knee and hip mobilization with progressive range of motion while no weight bearing was allowed for the first 60 days. Partial weight bearing was allowed after two months and full weight bearing after three months. At the last clinical and radiographic follow-up at 10 months the patient was able to walk with slight limp without aids. Left knee was stable but slightly stiff, with ROM 0-85° (Figure 6).

### Discussion

The removal of a bent femoral nail represents a challenge for the trauma surgeon. Different authors



**Figure 5.** Intraoperative photographs. A) Milling of the bent nail apex with diamond burs. Gauzes were positioned for soft tissue protection, together with continuous irrigation and suction. B) Nail breaking after milling is demonstrated



**Figure 6.** Ten months follow-up radiographs showing complete healing of both diaphyseal and distal femur fractures. A, B) AP view. C) Lateral view

have reported different techniques for the removal of a bent nail but there is no widely accepted algorithm

for their treatment (10, 16–18). The choice of the technique depends on the degree of deformity, on the direction of the deformity, the location of the deformity, on patient conditions and on the surgeon experience.

An adequate preoperative imaging is mandatory for precise individuation of magnitude and direction of the deformity and to plan both nail removal and definitive fracture treatment. Moreover, the vast majority of femoral bent nails present to the clinician after a high energy new trauma, differently from broken nails which usually occur in case of nonunion and often without trauma (13). Consequently, more soft tissue damage and associated lesions together with worse general conditions may be expected. In case of associated lesions, a damage control approach may be advantageous as it allows to stabilize the patient and to accurately plan definitive surgery. The technique described in the present paper resulted to be safe and effective, comparably to other techniques already reported. Moreover, it allowed to sequentially treat associated lesions without complications.

## Reference

1. Ricci WM, Gallagher B, Haidukewych GJ. Intramedullary nailing of femoral shaft fractures: current concepts. *J Am Acad Orthop Surg* 2009;17:296–305.
2. Kose, O., Guler, F., Kilicaslan, O.F. et al. *Arch Orthop Trauma Surg* (2016) 136: 195.
3. Biert J, Edwards MJ (2009) Re: Removal of a bent intramedullary nail with a posttraumatic sagittal plane deformity. *J Trauma* 67(5):1132–1133.
4. Patterson RH, Ramser JR Jr. Technique for treatment of a bent Russell-Taylor femoral nail. *J Orthop Trauma*. 1991;5:506–508.
5. Heffernan MJ, Leclair W, Li X (2012) Use of the f-tool for the removal of a bent intramedullary femoral nail with a sagittal plane deformity. *Orthopedics* 35(3):e438–e441.
6. Bek D, Demiralp B, Tunay S, Sehirlioglu A, Atesalp AS (2008) Removal of a bent inflatable femoral nail: a case report. *Acta Orthop Traumatol Turc* 42(3):211–213.
7. Aggerwal S, Soni A, Saini UC, Gahlot N (2011) Removal of a bent tibial intramedullary nail: a rare case report and review of the literature. *Chin J Traumatol* 14(2):107–110.
8. Bissonnette G, Laflamme GY, Alami GB, Rouleau D (2009) Management of a bent femoral intramedullary nail associated with an ipsilateral femoral neck fracture—a case report. *J Trauma* 67(2):E41–E43.
9. Apivatthakakul T, Chiewchantanakit S (2001) Percutaneous removal of a bent intramedullary nail. *Injury* 32(9):725–726.
10. Nicholson P, Rice J, Curtin J. Management of a refracture of the femoral shaft with a bent intramedullary nail in situ. *Injury* 1998;29(5):393–4.
11. Nicolaides V, Polyzois V, Tzoutzopoulos A, Stavlas P, Grivas TB, Korres D (2004) Bent femoral intramedullary nails: a report of two cases with need for urgent removal. *Eur J Orthop Surg Traumatol* 14:188–191.
12. Sakellariou VI, Kyriakopoulos S, Kotoulas H, Sofianos IP (2011) Bent intramedullary femoral nail: surgical technique of removal and reconstruction. *Case Rep Orthop* 2011:614509. doi:10.1155/2011/614509
13. Shen PC, Chen JC, Huang PJ, Lu CC, Tien YC, Cheng YM (2011) A novel technique to remove bent intramedullary nail. *J Trauma* 70(3):755–758.
14. Kritsaneephaiboon A, Tangtrakulwanich B, Maliwankul K (2012) A novel minimally invasive technique for removal of a bent femoral intramedullary nail. *Inj Extra* 43(12):157–162.
15. Gustilo RB, Anderson JT (1976) Prevention of infection in the treatment of one thousand and twenty-five open fractures of long bones: retrospective and prospective analyses. *J Bone Joint Surg Am* 58(4):453–458.
16. Singh R, Sharma AK, Kiranpreet. An innovative technique to cut and extract loose bent Kuntscher nail. *Indian J Med Sci* 2004;58(10):439–41.
17. Sonanis SV, Lampard AL, Kamat N, Shaikh MR, Beard DJ. A simple technique to remove a bent femoral intramedullary nail and broken interlocking screw. *J Trauma* 2007;63(2):435–8.
18. Banerjee R, Posner M. Removal of a bent intramedullary nail with a posttraumatic sagittal plane deformity. *J Trauma* 2009;66(5):1500–3.

Received: 26 October 2018

Accepted: 10 December 2018

Correspondence:

Canton Gianluca

Strada di Fiume 447 - 34149 Trieste (Italy)

Tel. +39 0403994730

Fax +39 0403994544

E-mail address: gcanton84@gmail.com