

C A S E R E P O R T

Can UKA after KineSpring system failure be a viable option? A case report

Giuseppe Niccoli, Paolo Di Benedetto, Daniele Salviato, Alessandro Beltrame, Renato Gisonni, Vanni Cainero, Araldo Causero

Department of Orthopaedic Surgery, University Hospital of Udine, Udine, Italy

Summary. *Background and aim of the Work:* The KineSpring System is an alternative treatment offered in selected symptomatic patients suffering from mild to moderate medial knee osteoarthritis (OA). This device reduces medial compartment loads in the OA knee without compromising the integrity of the lateral or patellofemoral knee compartments, maintaining the normal knee anatomy. Currently, papers about KineSpring System installation show promising results. The current authors describe a case of unicompartmental knee arthroplasty (UKA) employed to treat medial knee OA after Kinespring system failure. *Methods:* A 64-year old male patient presented to our hospital after failure of a Kinespring system implantation into his left knee at an external hospital, where the outcomes obtained were not satisfactory. The surgical options discussed with the patient were the TKA or medial UKA. A medial UKA was preferred by the patient. *Results:* One year from UKA, the patient complained of frequent joint effusions and weight bearing pain despite a good ROM without radiographic signs of implant loosening. Therefore, after two years we replaced UKA with total knee arthroplasty (TKA). *Conclusions:* Further experience is needed to provide reliable clinical data about the results of the UKA after KineSpring System discharge. (www.actabiomedica.it)

Key words: KineSpring System, failure, complications, revision surgery, unicompartmental knee arthroplasty

Background and aim of the Work

Medial Knee osteoarthritis (OA) is increased in middle-aged patients (1). When conservative treatment is not able to improve symptoms for long-term, surgical treatments are necessary to relieve pain and gain function (2). Total knee arthroplasty (TKA) should be used as a last option for the most severe cases of knee OA (3). High tibial osteotomy (HTO) is indicated in moderate to severe varus deformity associated with medial compartment overload/osteoarthritis (OA); while unicompartmental knee arthroplasty (UKA) is the viable option to treat medial knee OA with more neutral leg alignment (4, 5). A treatment gap between ineffective conservative treatment and invasive surgical options exists for early-onset medial knee OA (6). Patients are often young and show radiographic mild to

moderate OA with pain that limits their daily activities, above all participation in recreational sports (6). The development of new surgical options for younger patients is encouraged (7). The KineSpring knee implant System is an extra-articular and extra-capsular load absorber (8). This device has been proposed as an alternative treatment in selected symptomatic patients with mild to moderate medial knee OA (6, 9, 10). The purpose of this device is to stop the progression of the degenerative process, to relieve pain and to offer a minimally invasive joint sparing and reversible procedure (10). Initial research showed that the Kinespring system is able to provide a significant improvement in knee pain and function, a low complication rate and complete preservation of normal anatomy (9-11). The causes of KineSpring System failure reported in literature are infection, device breakage, intra- and extra-

articular metallosis and persistent pain, stiffness and flexion contracture (10, 12–15). These problems necessitate revision surgery. Our purpose is to describe the clinical course of a 64-year-old patient that underwent to UKA implant after Kinespring system explantation due to continuous pain and stiffness.

Methods

In May 2014, a 64-year-old man underwent a kinespring system implantation in a different orthopedic institution for symptomatic medial overload of the left knee (Fig. 1). This surgical treatment was not successful: the left knee was painful at weight bearing and at rest and stiff with ROM of 10° to 80° for extension and flexion. For these reasons the device was removed in June 2015 by the same surgeon. The surgical excision of the femoral and tibial scars revealed extra-articular metallosis and severe fibro-calcific scar reaction around the implant. The patient then underwent intra-articular hyaluronic acid injections without meaningful benefit, the knee remained very symptomatic with slight lameness upon walking. In December 2015 the patient was assessed at our institution. Clinical examination revealed bilateral varus malalignment of the lower limb and flexion contracture <15 degrees. The left knee showed signs of profuse joint effusion and medial knee compartment tenderness. There was no varus/valgus and anterior/posterior instability on clinical examination. There were no clinical signs of infection or neurological deficits. The range of motion (ROM) of the left knee was 10° to 120° for extension

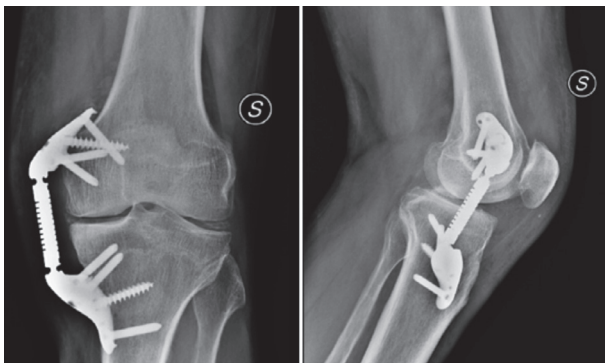


Figure 1. Radiographs of the left knee showing Kinespring system installation

and flexion, respectively. Standard knee X-rays, axial patellar projections, and weight-bearing full-length lower limb radiographs showed medial knee OA (Fig. 2). Magnetic resonance imaging (MRI) of the knee showed advanced degenerative changes in the medial compartment, with all other knee compartments in good shape (Fig. 3). Blood analysis and inflammatory markers (leukocytes counts, ESR, CRP) were normal. Treatment with prosthetic replacement was indicated. The surgical options discussed with the patient were the TKA or medial UKA (16). A medial UKA was preferred by the patient and an elective UKA was planned. On admission in May 2016, his body mass index (BMI) was 26.86 kg/m² (1.76 m; 83 kg) and preoperative assessment included the following scores:

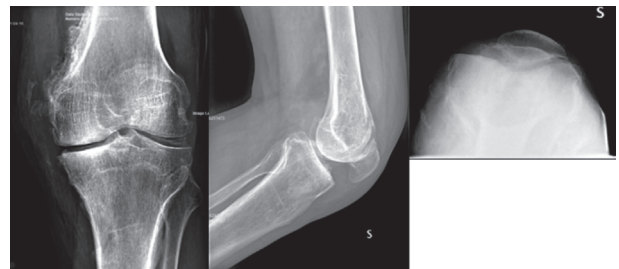


Figure 2. Preoperative radiographs of the left knee showing medial knee OA after Kinespring system explant

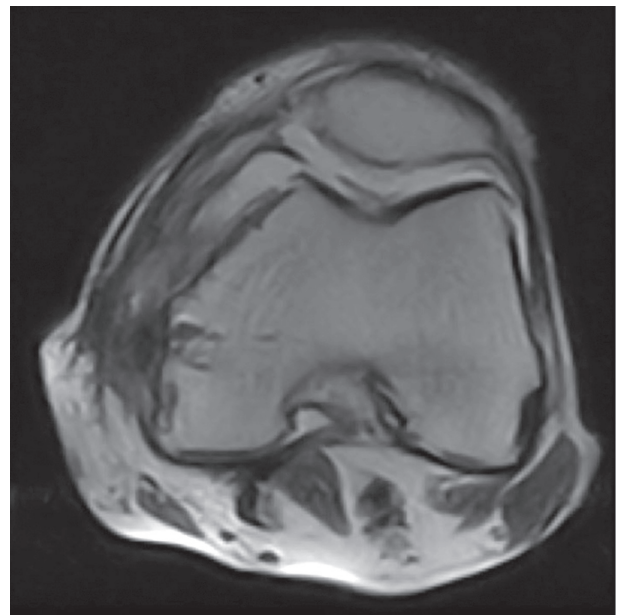


Figure 3. Preoperative MRI of the left knee showing patellofemoral joint of left knee in good shape

KSS 40, WOMAC score 67.4, IKDC score 28.7 and VAS pain score 9.

Surgical exploration revealed anteromedial knee OA (Fig. 4) and a free lateral compartment. A chondral lesion of the 4th degree according to the Outerbridge classification, about 1 cm in diameter, was detected on the femoral trochlea, with osteophyte below the patella. Anterior cruciate ligament (ACL) was undamaged. Therefore, in agreement with the patient, surgeons implanted a medial UKA (ZUK-Lima) in the left knee (Fig. 5). Postoperative clinical course over two weeks was complications free, with a ROM of 0-90° and mild joint effusion. Weight bearing with Canadian crutches and physiokinesitherapy (PKT) program was allowed on the first postoperative day. One month and three months after surgery clinical examination showed mild knee joint effusion and ROM of 10° to 110°. The knee extension deficit was partially reducible. There was no joint instability. We recommended continuation of the PKT program for recovering ROM and muscle tone, stressing on knee extension recovery.

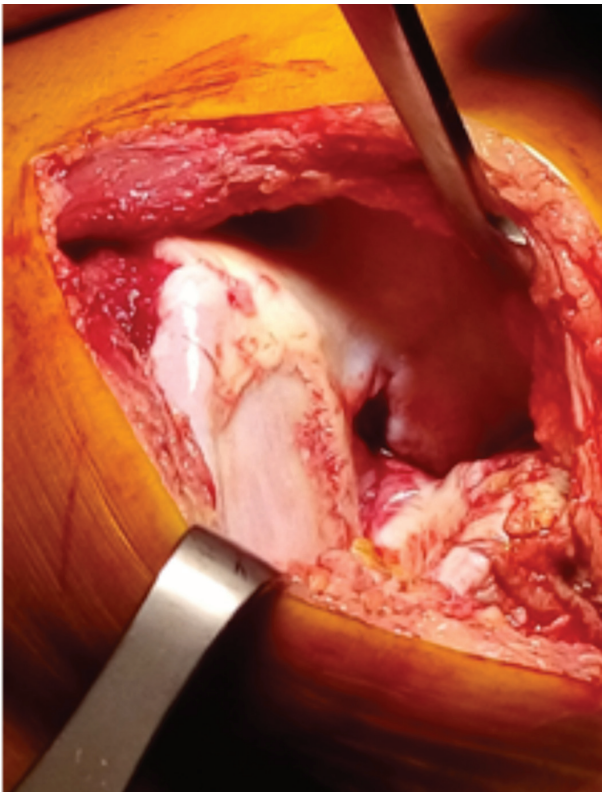


Figure 4. Intraoperative image revealing knee anteromedial OA

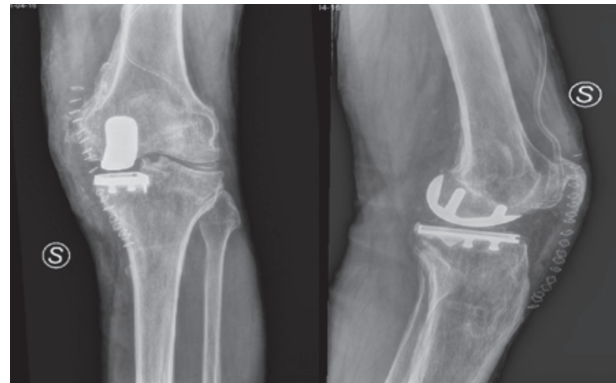


Figure 5. Postoperative radiographs of the left knee following UKA implantation

Results

Six months after surgery, the patient reported improvement in pain and ROM. Clinical examination showed no knee joint effusion, a persistent partially reducible knee extension deficit of about 10°, (like the controlateral knee), knee flexion of 120°, and no joint instability. The functional scores showed a moderate improvement: KSS 66, WOMAC score 73.5, IKDC score 67.8 and VAS pain score 3 with mild pain during up- and down-stairs ambulation.

One year after replacement, patient reported some pain during daily activity and recurrent joint effusions. Range of movement (ROM) of left knee was 10° to 100°, functional scores were the same as previously. Knee X-rays were performed at each clinical follow-up. There were no signs of prosthetic loosening or osteolysis. We recommended continuation of the PKT program to improve symptoms and function.

The patient returned for a 2-year follow-up after surgery (Fig. 6) showing the same problems and a mildly swollen left knee. There were no clinical signs of knee infection. Therefore, the revision of UKA to TKA was recommended in agreement with the patient and an elective TKA was implanted (Fig. 7).

Conclusions

More than 4 million Americans suffer from knee OA compromising walking ability (6, 17). Only 500,000 knee arthroplasties and HTOs are performed

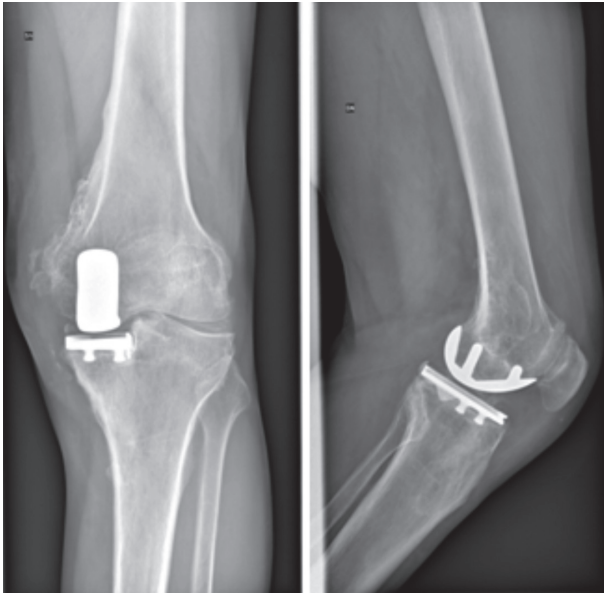


Figure 6. Radiographs of the left knee following UKA implantation after 2 year of replacement

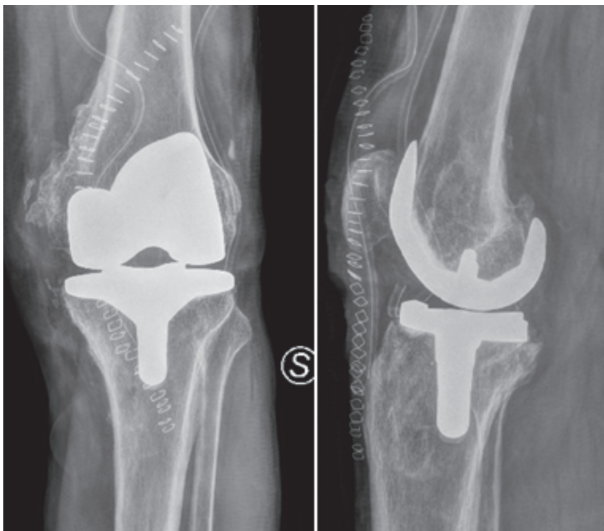


Figure 7. Postoperative RX of the left knee following TKA replacement

annually in America, representing only 13% of all patients with debilitating symptoms (18). These estimates are due to the fact that many patients are in the treatment gap between ineffective conservative treatment and invasive surgical options for many years (6).

The Kinespring implant has been proposed as an effective alternative to HTO and UKA when mild to moderate but symptomatic medial OA affects the knee

(6, 9, 10). The Kinespring system would fill the treatment gap for those OA patients who are no longer relieved by palliative and/or conservative treatment and who are not willing to consider arthroplasty or osteotomy, or for whom arthroplasty or osteotomy are not indicated (8).

However, patients must be correctly selected according to the inclusion and exclusion criteria showed in literature (9, 10, 15). This device seems to be a true tissue sparing procedure that does not alter the knee biomechanics, and is readily accepted by patients due to the reversible nature of the procedure (9, 10). The Kinespring system reduces medial compartment loads in the OA knee without compromising the integrity of the lateral or patellofemoral compartments (19). This system can modify the progression of knee OA by increasing the joint space and improving subchondral bone trabecular integrity (20). Theoretically, anatomical structure remain intact with this implant and the device may be explanted, if needed, via the same access route without compromising future surgical options (19).

Reports that have examined the effectiveness of the Kinespring system carried out a follow-up after 12 months, 2 years and 5 years. Currently, papers about Kinespring system installation show promising results (6, 10, 15, 20).

Previous research has suggested that with a five-year lifespan of the implant, the Kinespring system demonstrates significant economic advantage over other surgeries and conservative methods (21). However, this device is not complication-free. Infection, device breakage, intra- and extra-articular metallosis, mechanical failure, soft tissue intolerance and very difficult to diagnose and to treat knee pain are listed (10, 12-15) among the complications.

These complications, thus, represent a problem necessitating revision surgery and device explant. Further research regarding the biomechanics and risks of the Kinespring system implantation and explantation are needed. Indeed, local intra- and extra-articular metallosis, soft tissue damage especially to the medial joint capsule and the medial collateral ligament, synovitis and joint effusion due to intrarticular metallosis and medial joint instability after device explant can make subsequent surgical treatment difficult (14).

Bowditch et al. (12) reported device infection after 6 weeks following surgery. The load absorber system was removed and antibiotic treatment was performed. New Kinespring system was implanted 3 months later, after the infection resolved.

Citak et al. (13) removed Kinespring 7 months after its installation due to device breakage and they recommended TKA for extensive metallosis and OA spread to other knee compartments.

Also Schüttler et al. (14) recommended TKA after Kinespring explants. They found extensive synovitis and metallosis, elevated chromium ion levels, full thickness cartilage erosion on the medial femoral condyle and the tibia, joint capsule disruption and medial instability.

Hayes et al., (15) in their case series of 12 patients, reported one patient with knee stiffness at 1,5 years after surgery then resolved, and one patient with deep infection resolved after antibiotic therapy.

Recently, Madonna et al. (10) showed their preliminary results after Kinespring implant in 53 patients after 12 months of follow-up. In 5 of 53 patients revision surgery was necessary. Kinespring system was removed in one patient due to infection after 2 months from surgery and in two patients the implant was explanted after 8 and 10 weeks from surgery due to pain and stiffness that were not resolved.

Our report is the first case of medial UKA implantation after Kinespring system failure. Although after 6 months we have not seen full recovery of range of motion, the patient was satisfied and reported improvement in knee pain and function. However, after two years we replaced UKA to TKA due to continuous painful UKA appeared one year after surgery.

The choice of UKA implantation allows more bone preservation, quicker recovery, decreased blood loss, lower serious complication rate, lower cost, as well as improved range of motion, joint kinematics, and proprioception compared to TKA (22). Preoperative diagnosis, history of prior knee surgery, choice of implant, and patient gender did not seem related with KSS score or the need for revision surgery (23). Performing TKA after HTO is more challenging due to loss of tibial bone stock, soft-tissue scarring, altered slope of the posterior tibial plateau and a shortened patellar tendon. Knee malalignment is more frequent

in TKA after HTO than primary TKA and this could be a possible factor accounting for the lower outcomes reported after this procedure (24). Valenzuela GA et al. (24) proved that prior HTO does not affect clinical outcome of a UKA. The results of patients who underwent UKA after HTO are comparable to those of TKA after HTO or primary UKA. UKA revision due to persistent pain and arthrofibrosis was performed in 1.8% and 2.5% (25) of patients, respectively, and outcomes of revision UKA to TKA were similar to primary TKA (26). When the Kinespring knee implant fails, it is important to know that the medial UKA is probably not a viable option, even when the indications for UKA are still present (5). We consider Kinespring implantation non a tissue sparing surgery due to soft-tissue scarring, joint capsule disruption, medial instability and its replacement requires a revision TKA often constrained. In conclusion HTO and UKA are still the most viable solutions to treat medial OA considering the potential advantages of delaying the eventual TKA and the fact that most patients with HTO and UKA rarely undergo revision surgery (27). Further experience is needed to provide reliable clinical data about the results of the UKA after KineSpring System discharge.

References

1. Zhang Y, Jordan JM. Epidemiology of osteoarthritis. *Clin-GeriatrMed*. 2010;26:355-369
2. Crawford DC, Miller LE, Block JE. Conservative management of symptomatic knee osteoarthritis: a flawed strategy? *OrthopRev (Pavia)* 2013;5:e2
3. Rönn K, Reischl N, Gautier E, Jacobi M. Current surgical treatment of knee osteoarthritis. *Arthritis [Internet]*. 2011. Available at: <http://www.hindawi.com/journals/arthritis/2011/454873/>.
4. Rossi R, Bonasia DE, Amendola A. The role of high tibial osteotomy in the varus knee. *J Am AcadOrthop Surg*. 2011 Oct;19(10):590-9.
5. Dettoni F, Bonasia DE, Castoldi F, Bruzzone M, Blonna D, Rossi R. High tibial osteotomy versus unicompartmental knee arthroplasty for medial compartment arthrosis of the knee: a review of the literature. *The Iowa Orthopaedic Journal*. 2010;30:131-140.
6. London NJ, Miller LE, Block JE. Clinical and economic consequences of the treatment gap in knee osteoarthritis management. *MedHypotheses*. 2011;76:887-92.
7. Carr AJ, Robertsson O, Graves S, et al. Knee replacement. *Lancet*. 2012;379: 1331-40

8. Gabriel SM, Clifford AG, Maloney WJ, et al. Unloading the osteoarthritic knee with a novel implant system. *J Appl Biomech*. 2013;29:647-654.
9. Clifford AG, Gabriel SM, O'Connell M, Lowe D, Miller LE, Block JE. The KineSpring® Knee Implant System: an implantable joint-unloading prosthesis for treatment of medial knee osteoarthritis. *Medical Devices (Auckland, NZ)*. 2013;6:69-76.
10. Madonna V, Condello V, Piovan G, Screpis D, Zorzi C. Use of the KineSpring system in the treatment of medial knee osteoarthritis: preliminary results. *Joints*. 2015;3(3):129-135.
11. Li CS, Poolman RW, Bhandari M. Treatment preferences of patients with early knee osteoarthritis: a decision board analysis assessing high tibial osteotomy versus the KineSpring® knee implant system. *J Long Term Eff Med Implants*. 2013;23(2-3):175-88.
12. Bowditch M, Miller LE, Block JE. Successful two-stage revision of a KineSpring® joint unloading implant: a case study. *International Medical Case Reports Journal*. 2012;5:91-95.
13. Citak M, Kendoff D, O Loughlin PF, Klatte TO, Gebauer M, Gehrke T, Haasper C. Failed joint unloading implant system in the treatment of medial knee osteoarthritis. *Arch Orthop Trauma Surg*. 2013 Nov;133(11):1575-8.
14. Schüttler KF, Roessler M, Fuchs-Winkelmann S, Efe T, Heyse TJ. Failure of a Knee Joint Load Absorber: Pain, Metallosis and Soft Tissue Damage. *HSS Journal*. 2015;11(2):172-176.
15. Hayes DA, Waller CS, Li CS, Vannabouathong C, Sprague S, Bhandari M. Safety and Feasibility of a KineSpring Knee System for the Treatment of Osteoarthritis: A Case Series. *Clinical Medicine Insights Arthritis and Musculoskeletal Disorders*. 2015;8:47-54.
16. Vasso M, Antoniadis A, Helmy N. Update on unicompartmental knee arthroplasty: Current indications and failure modes. *EFORT Open Rev*. 2018 Aug 1;3(8):442-448. doi: 10.1302/2058-5241.3.170060. eCollection 2018 Aug.
17. Dillon CF, Rasch EK, Gu Q, Hirsch R. Prevalence of knee osteoarthritis in the United States: arthritis data from the Third National Health and Nutrition Examination Survey 1991-94. *Journal of Rheumatology*. 2006;33(11):2271-2279.
18. National statistics on all stays: 2005 outcomes by patient and hospital characteristics for ICD-9-CM principal procedure code 81.54 total knee replacement. <http://hcupnet.ahrq.gov/Hcupnet.jsp>.
19. Hayes DA, Miller LE, Block JE. Knee Osteoarthritis Treatment with the KineSpring Knee Implant System: A Report of Two Cases. *Case Reports in Orthopedics*. 2012.
20. Miller LE, Sode M, Fuerst T, Block J. Joint unloading implant modifies subchondral bone trabecular structure in medial knee osteoarthritis: 2-year outcomes of a pilot study using fractal signature analysis. *Clin Interv Aging*. 2015;10:351-7.
21. Li CS, Seeger T, Auhuber TC, Bhandari M. Cost-effectiveness and economic impact of the KineSpring® knee implant system in the treatment for knee osteoarthritis. *Knee Surg Sports Traumatol Arthrosc*. 2013;21(11):2629-37.
22. Noticewala MS, Geller JA, Lee JH, et al. Unicompartmental knee arthroplasty relieves pain and improves function more than total knee arthroplasty. *J Arthroplasty* 2012;27:99.
23. Thompson SA, Liabaud B, Nellans KW, Geller JA. Factors associated with poor outcomes following unicompartmental knee arthroplasty: redefining the "classic" indications for surgery. *J Arthroplasty*. 2013 Oct;28(9):1561-4.
24. Valenzuela GA, Jacobson NA, Buzas D, Koreckij TD, Valenzuela RG, Teitge RA. Unicompartmental knee replacement after high tibial osteotomy: Invalidating a contraindication. *Bone Joint J*. 2013 Oct;95-B(10):1348-53.
25. Citak M, Dersch K, Kamath AF, Haasper C, Gehrke T, Kendoff D. Common causes of failed unicompartmental knee arthroplasty: a single-centre analysis of four hundred and seventy one cases. *Int Orthop*. 2014 May;38(5):961-5.
26. Levine WN, Ozuna RM, Scott RD, et al. Conversion of failed modern unicompartmental arthroplasty to total knee arthroplasty. *J Arthroplasty* 1996;11:797.
27. Robertsson O, W-Dahl A. The risk of revision after TKA is affected by previous HTO or UKA. *Clin Orthop Relat Res*. 2015 Jan;473(1):90-3

Received: 26 October 2018

Accepted: 10 December 2018

Correspondence:

Paolo di Benedetto, MD, PhD,
Department of Orthopaedic Surgery,

University Hospital of Udine,

P.le S.Maria della Misericordia 15 - 33100 Udine, Italy

Tel. +39 0432 559464 - Fax +39 0432 559298

E-mail: paolo.dibenedetto@asuud.sanita.fvg.it