

Atypical use of pediatric flexible nails in the treatment of diaphyseal fractures in adults

Alessio Pedrazzini¹, Paolo Bastia², Nicola Bertoni¹, Bianca Pedrabissi¹, Henry Claudel Yerwo Simo¹, Vanni Medina¹, Francesco Ceccarelli², Francesco Pogliacomì²

¹ Orthopaedic Unit, Oglio Po Hospital, Vicomoscato di Casalmaggiore (CR), ASST Cremona, Italy; ² Orthopaedics and Traumatology Clinic, Department of Medicine and Surgery, University of Parma, Parma, Italy

Summary. *Background and aim of the work:* Elastic intramedullary nails are commonly used for the treatment of diaphyseal fractures in adolescents and children. The major advantages are the minimally invasive nature of the technique, the short operation time, and the preservation of the growth plate and periosteum thus allowing bone healing within a closed and intact biological environment. Elastic nails are rarely applied to the adult fractures. *Methods:* Five selected adult patients affected by diaphyseal fractures were treated using paediatric flexible nails T2 Kids (Stryker®, Mahwah, NJ, USA) as consequence of their poor clinical conditions, high risk of neurovascular injuries and skin/soft tissues problems. All patients were monthly clinically and radiographically evaluated after surgery until fracture healing. *Results:* Radiological and clinical outcomes were satisfying. All fractures healed after a mean period of 3 months. No losses of reduction as well as mobilization/breakage of implant were observed. *Conclusions:* Use of pediatric elastic nails is a valid surgical option in treatment of diaphyseal fractures in selected adult patients who request fast and minimally invasive surgery as consequence of precarious clinical or soft tissues conditions. (www.actabiomedica.it)

Key words: elastic nailing, diaphyseal fractures, adults

Introduction

Elastic intramedullary nailing is widely used to treat long bones fractures in children and adolescents (1-3). This technique preserves the integrity of the growth plates and the periosteum thus allowing bone healing within a closed and intact biological environment (4, 5). The use of elastic stable intramedullary nails is intended for fixation of diaphyseal fractures of long bones where the medullary canal is narrow, and flexibility of the implant is of paramount importance. The biomechanical principle of this technique is based on the symmetrical bracing action of two elastic nails inserted into the metaphysis, which bears against the inner bone in three points (6, 7). This method has the benefits of early immediate stability to the involved

bone segment, which permits early mobilization and return to the normal activities of the patients, with very low complication rate (8). By contrast, adult bone healing properties are diminished compared with that of children. Osteoblasts in the inner cellular layer of the child's thick periosteum become thinner with age, and the bone healing process is also prolonged with aging.

For these reasons elastic nails are usually applied to pediatric population due to the thick periosteum and the increased potential for bone remodelling in children, but they are not routinely used in adults because of lack of resistance to rotational force and axial loading (4, 5).

Nevertheless, intramedullary elastic nailing offers a safe, rapid and minimally invasive surgical option for

the fixation of fractures of long bones in selected adult patients characterized by precarious general clinical or local soft tissues conditions. The aim of this study is to analyze the outcomes of 5 selected adult patients affected by long bones fractures and operated on with

flexible nail T2 Kids (Stryker®, Mahwah, NJ, USA) in which open reduction and internal fixation (ORIF) or static intramedullary nailing (IM) was contraindicated.

Materials and methods

All subjects were treated during 2018; this surgical option was chosen for their low functional needs, high risk of neurovascular injuries and skin/soft tissues bad conditions in order to facilitate post-operative care. All patients were monthly clinically and radiographically assessed (mean follow-up of patients was 8.5 months) until fracture healing.

Case 1 (figure 1)

A 28 years-old male reported an isolated fourth proximal radial shaft fracture after a fall during a football match. The surgical approach had a high risk of posterior interosseous nerve injury. Therefore, the fracture was reduced using one elastic nail introduced

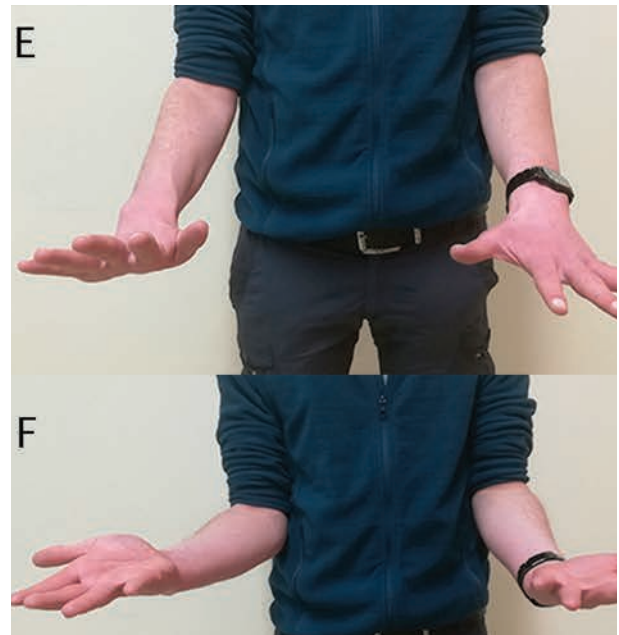
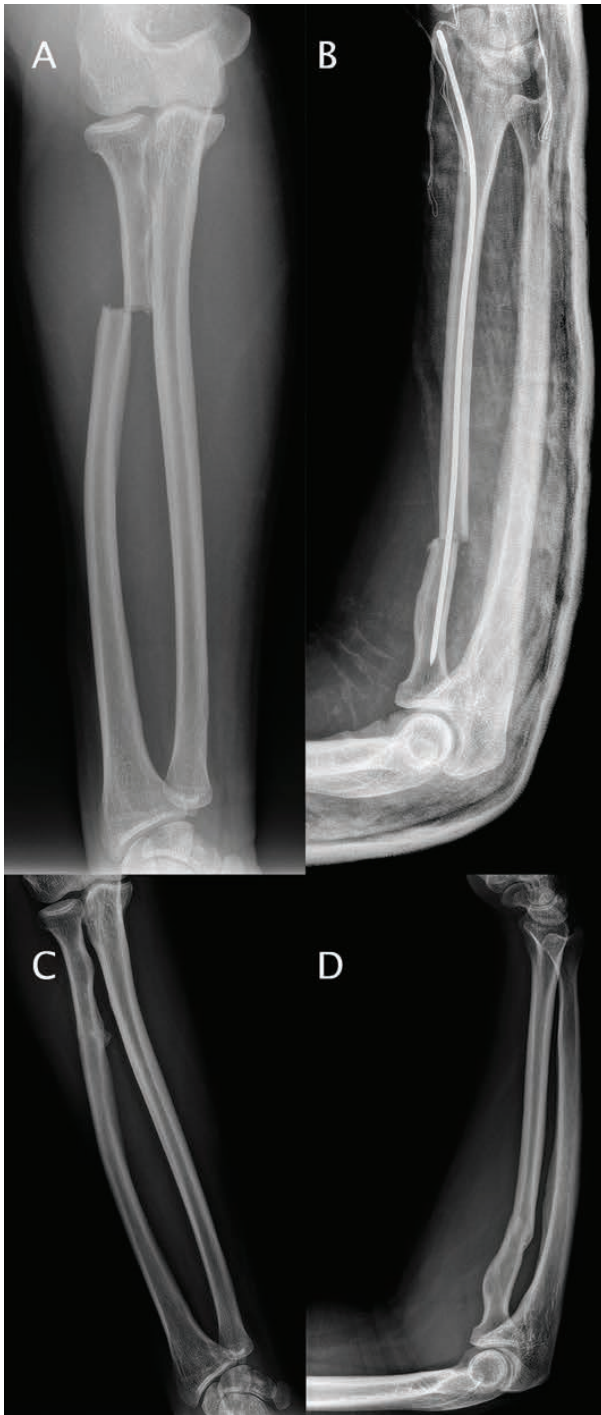


Figure 1. Pre-operative (A) and post-operative X-rays (B). Fracture's healing 7 months after surgery (C and D). No limitation of strength and of ROM at clinical evaluation (E and F)

through distal epiphyseal radius. Surgery lasted 45 minutes. The patient was discharged the following day with no evidence of peripheral vascular-nervous impairment. The elbow joint was initially immobilized with plaster cast for 1 month and after its removal the patient started rehabilitation program. Radiographic control performed 1.5 months after surgery showed initial bone consolidation and healing; T2 Kids nail was removed 4 weeks later. The patient was satisfied; nowadays, there are no limitations of strength and of range of motion (ROM) and no pain or vascular-nervous impairment has been reported. Last X-ray was performed 7 months after surgery and complete fracture's healing was observed.

Case 2 (figure 2)

A 70 years-old female came to our attention with a third distal humeral multifragmentary fracture. The

patient had suffered a previous humeral head fracture 20 years before treated conservatively and for this reason shoulder mobility was already reduced. Management of the injury was very difficult because of severe concomitant pathologies [clinical history of rheumatoid arthritis (AR) in treatment with corticosteroid and cardiac disease in treatment with Clopidogrel] and skin conditions that contraindicated open reduction and internal fixation (ORIF) even if a radial nerve impairment was present. The fracture was synthesized with a K-wire introduced through a percutaneous transolecranic access in order to stabilize distal fragments and a flexible intramedullary nail T2 Kids introduced proximally. Time of surgery was 1 hour. The post-operative course was uneventfully and the patient was discharged 1 week later. A gradual recovery of motility and sensitivity in the radial nerve area in the following weeks was reported. Cast was removed 30 days after surgery and nail and K-wire 1 month later. Despite the poor quality of bone tissue, following

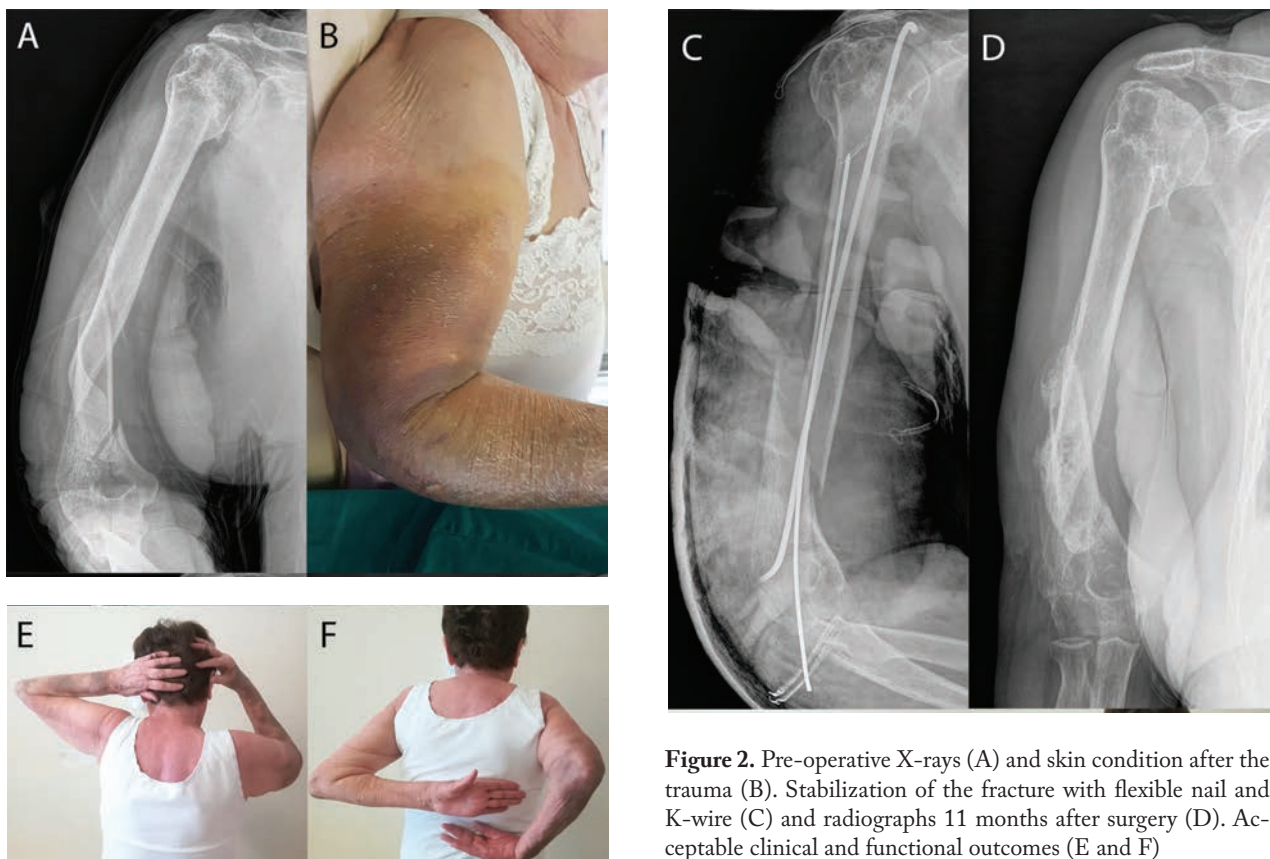


Figure 2. Pre-operative X-rays (A) and skin condition after the trauma (B). Stabilization of the fracture with flexible nail and K-wire (C) and radiographs 11 months after surgery (D). Acceptable clinical and functional outcomes (E and F)

controls showed acceptable clinical outcomes and 11 months after surgery the patient fully recovered. ROM of shoulder wasn't further reduced and she didn't refer pain or peripheral neurovascular or strength's deficits.

Case 3 (figure 3)

A 68 years-old female reported a complex fracture of proximal humerus. After admission blood exams revealed a persistent leukocytosis with no apparent causes. Due to the increased infectious risk a minimally invasive surgical option of treatment was performed using 2 paediatric flexible nails T2 Kids. Surgery lasted 50 minutes. Post-operative course was regular and the patient had no fever at discharge. The arm was immobilized with a Desault brace for 40 days and external

rotation movements were initially forbidden. X-ray controls were performed monthly and showed bone consolidation and healing of the injury 2 months after treatment followed by nails removal and rehabilitation. Following controls confirmed a progressive good clinical and radiographic evolution as well as the last one, performed 11 months after surgery, in which the patient has minimal limitation of ROM in extreme external rotation and no pain or vascular-nervous deficit were reported.

Case 4 (figure 4)

A 76 years-old female with a history of AR and osteoporosis came to our attention with a diaphyseal humeral fracture with involvement of the surgical neck

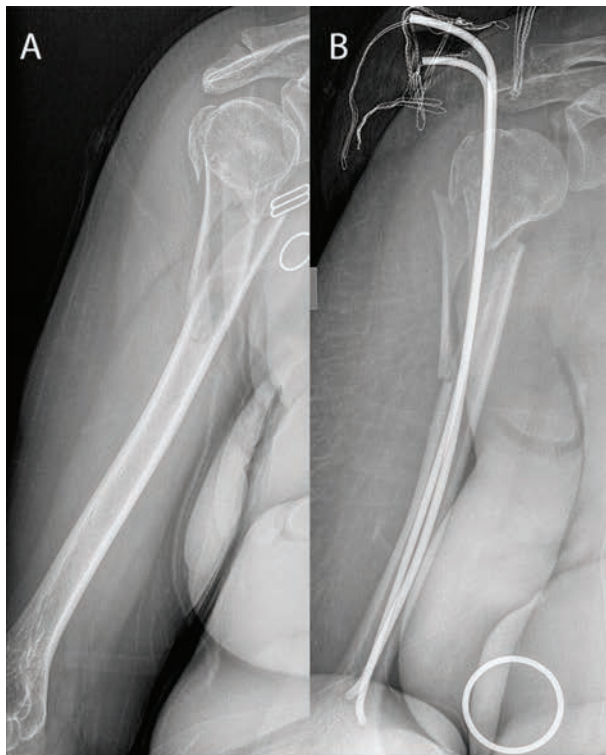
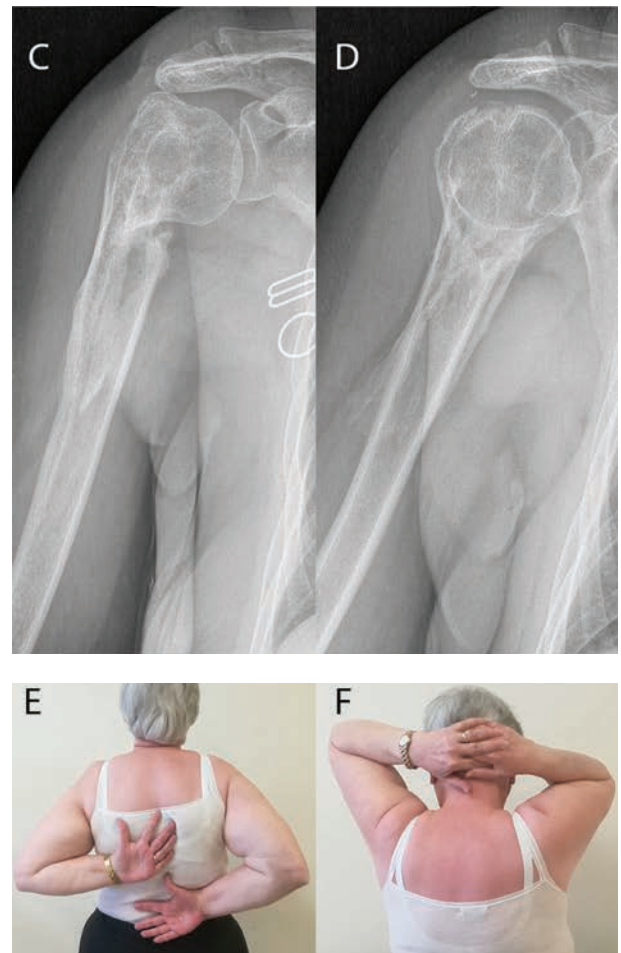


Figure 3. Pre-operative (A) and post-operative X- rays (B). Radiographic controls performed 11 months later (C and D). Residual limitation of ROM in maximal degrees of external rotation at clinical assessment (E and F)



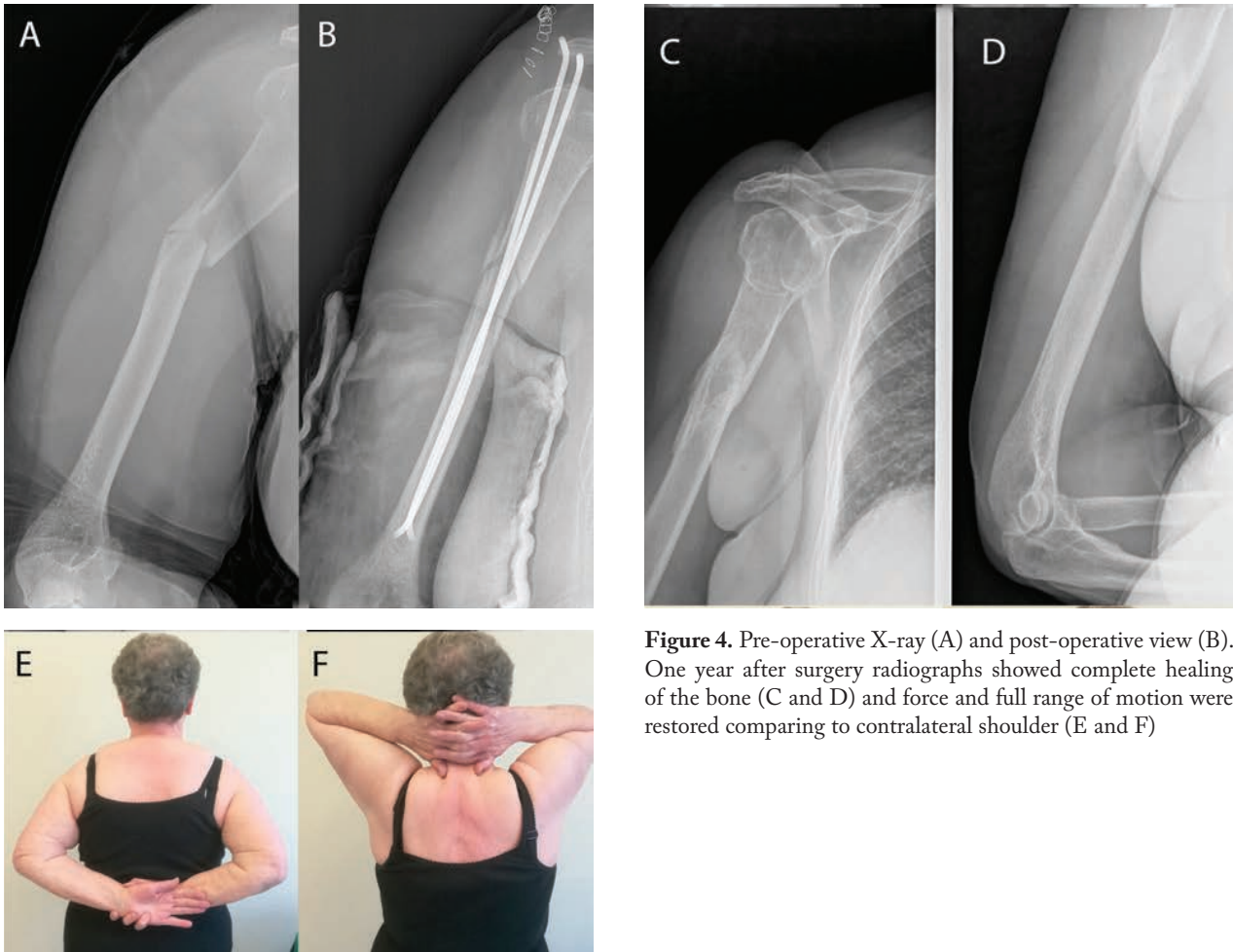


Figure 4. Pre-operative X-ray (A) and post-operative view (B). One year after surgery radiographs showed complete healing of the bone (C and D) and force and full range of motion were restored comparing to contralateral shoulder (E and F)

following a fall at home. The fracture was treated using 2 elastic nails T2 Kids introduced through proximal mini-access. In this case a minimally invasive surgical option was used because of higher low functional needs and in order to facilitate post-operative recovery. Time of surgery was 1 hour. The elbow joint was immobilized at 90° of flexion with plaster cast. After clinical stabilization the patient was discharged. Plaster was removed 2 months later and radiograph and clinical controls were performed monthly. Bone healing was observed 3 months after surgery followed by removal of the nails. The patient started active and passive rehabilitation 2 weeks after nails removal. X-ray and clinical follow-up continued with no evidence of complications and 12 months after surgical treatment the patient regained complete ROM without pain or any strength's deficit.

Case 5 (figure 5)

A 14 years-old male reported a third proximal humeral fracture after a car accident. Due to the type of fracture and the young age elastic nailing was performed. However, conventional distal entry point of nail (2-3 cm proximally to lateral humeral epicondyle) is very close to the radial nerve and caution is required in order to avoid it. Therefore, a single posterior access through triceps muscle was utilized to introduce T2 kids nails and to reduce the risk of nervous injury. The surgery lasted 70 minutes. The patient was discharged the following day and no post-operative complications were observed. Desault brace was applied to immobilize the operated arm for 40 days and pulsed electromagnetic fields was performed for 1 month in order to accelerate bone healing. After brace's removal the pa-

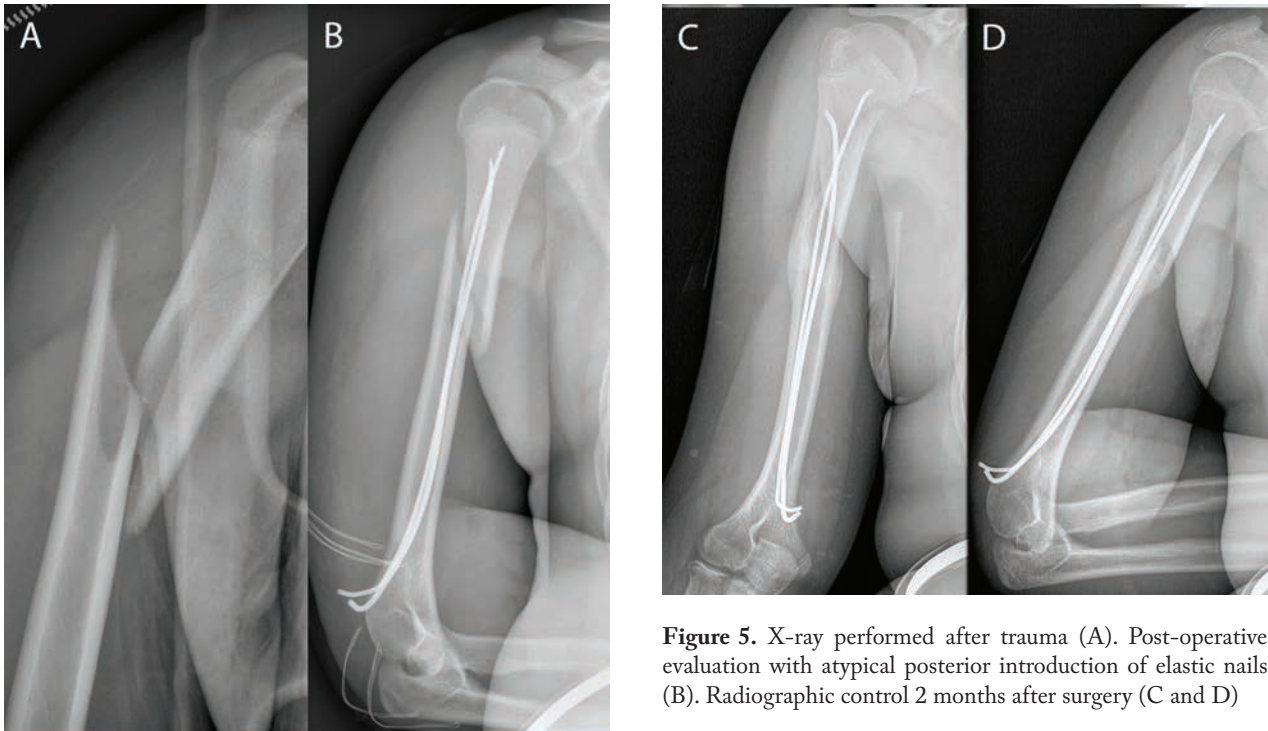


Figure 5. X-ray performed after trauma (A). Post-operative evaluation with atypical posterior introduction of elastic nails (B). Radiographic control 2 months after surgery (C and D)

tient started rehabilitation program. Last X-ray control performed 50 days after surgery from treatment shows complete bone consolidation. Nowadays, there are no limitations of strength and of ROM and no vascular-nervous deficits were reported. The patient does not report any pain and he is waiting for nails removal.

Discussion

The elastic nailing method was first described by Rush; it is based on the “3-point fixation principle” when introduced in the medullary canal of long bones. It was first used for the treatment of long bones fractures of lower extremities and soon became a very popular method for all long bone synthesis.

Elastic nails are rarely applied to the adult fractures because of lack of resistance to rotational force and axial loading (4, 5).

Elastic stable intramedullary nails (ESIN) are commonly used for the treatment of long bone fractures in adolescents and children (1-3). The major ad-

vantages are the minimally invasive nature of the technique, the short operation time, and the preservation of the growth plate and the periosteum thus favouring bone healing within a closed and intact biological environment. The aim of the treatment is to achieve a level of reduction and stabilization that is appropriate to the age of the child. The biomechanical principle of the technique is based on the symmetrical bracing action of two elastic nails inserted into the metaphysis, each of which bears against the inner bone at three points (6, 7). This produces immediate flexural, axial, translational and rotational stability thus permitting early mobilization and return to the normal activities of the patients, with low complication rate (6,9-11).

Nevertheless, in selected adult patients in which clinical and cutaneous conditions contraindicate ORIF or rigid IM nailing, this type of fixation may be still used as well demonstrated in the literature.

The effectiveness of flexible nailing as a treatment modality for humeral shaft fractures has been assessed by many studies (12-15). Most of these studies have used Ender’s nail as a method of nailing (16, 17).

In a study to evaluate clinical outcome, Verma et al. have seen that titanium elastic nail system is a good alternative for treatment of diaphyseal fractures of humerus in adult age group as it requires minimum invasive approach, can achieve union without disturbing the biology of fracture site (18).

In 2014 Modi et al. compared the outcome of titanium elastic nail and plate in the adult shaft humerus fractures and concluded that results of titanium elastic nails in union rates and union time were good and comparable to plates with lesser rate of complications, but their usefulness is limited to middle third fractures of humerus. The results of titanium elastic nail depend greatly on jamming of canal, control of rotation, and proximity of fracture to entry point (19).

A preliminary study of 2011 by Kim et al. suggested that percutaneous flexible nailing and intramedullary cementing could be an optional treatment modality for surgical palliation of selected high-risk terminal cancer patients with metastases to the humerus (20).

Various nails such as elastic stable intramedullary nails (ESIN) and locking flexible clavicular nails were widely used in treatment of midclavicular fractures (21). In 2002, titanium elastic nail was firstly applied in the treatment of displaced midclavicular fractures and showed good clinical therapeutic outcomes, but commonly it might induce various complications, including hardware irritations, medial perforations, lateral penetrations, TEN breakage and dislocation (22, 23).

In the past, elastic Ender nails were used in the treatment of osteoporotic pertrochanteric fractures in aged people and of tibial shaft fractures with good results (24, 25).

In 2009 Khurana et al. treated a series of adult patients with humeral shaft fractures with retrograde Ender nails with satisfactory results and low rate of complications (26).

In a case report of 2015 Quiang et al. reported that application of the elastic nail in the fixation of the fibula can simplify the surgical procedure, maintain the stability, and lower-extremity alignment in the treatment of complicated tibia and fibula fractures. (27).

The use of elastic nails provides an alternative means for internal fixation of adult proximal radial fractures and there are few reports about this (28, 29).

The proximal radius is surrounded by abundant forearm muscle and the posterior interosseous nerve (PIN) crosses this area. The intramedullary nail method has advantages such as closed application, less soft tissue injury, avoidance of nerve injury, and cosmetic benefits compared with the standard procedure of open reduction with plate and screw fixation. A recent study of Huang et al. (2018) evaluated the functional outcomes and efficiency of elastic nailing in the surgical treatment of adult proximal radial shaft fractures and most patients achieved desirable functional outcomes (30).

Results of this paper confirm these assumptions and demonstrate that intramedullary elastic nailing is a safe and minimally invasive surgical option in order to stabilize diaphyseal long bones fractures also in selected adult patients and in particular clinical conditions with satisfactory radiological and functional outcomes.

Conclusions

According to this study's assessment, the use of paediatric flexible nails T2 Kids (Stryker®, Mahwah, NJ, USA) is a good surgical option in treatment of selected adult patients who request fast and minimally invasive surgery due to precarious clinical or soft tissues conditions, not high functional requests, old age or when ORIF or static IM nailing is contraindicated.

Conflict of interest: Each author declares that he or she has no commercial associations (e.g. consultancies, stock ownership, equity interest, patent/licensing arrangement etc.) that might pose a conflict of interest in connection with the submitted article

References

1. Nielsen E, Bonsu N, Andras LM, Goldstein RY. The effect of canal fill on paediatric femur fractures treated with titanium elastic nails. *J Child Orthop* 2018; 12(1): 15-19.
2. Popkov A, Foster P, Gubin A, Borzunov D, Popkov D. The use of flexible intramedullary nails in limb lengthening. *Expert Rev Med Devices* 2017; 14(9): 741-753.
3. Heare A, Goral D, Belton M, Beebe C, Trizno A, Stoneback J. Intramedullary implant choice and cost in the treatment of pediatric diaphyseal forearm fractures. *J Orthop Trauma* 2017; 31(10): e334-e338.

4. Sinikumpu JJ, Serlo W. The shaft fractures of the radius and ulna in children: current concepts. *J Pediatr Orthop B* 2015; 24(3): 200-206.
 5. Antabak A, Luetic T, Ivo S, et al. Treatment outcomes of both-bone diaphyseal paediatric forearm fractures. *Injury* 2013; 44 (Suppl 3): S11-S15.
 6. Li Y, Stabile KJ, Shilt JS. Biomechanical analysis of titanium elastic nail fixation in a pediatric femur fracture model. *J Pediatr Orthop* 2008; 28(8): 874-878.
 7. Mahar A, Sink E, Faro F, Oka R, Newton PO. Differences in biomechanical stability of femur fracture fixation when using titanium nails of increasing diameter. *J Child Orthop* 2007; 1(3): 211-215.
 8. Pogorelić Z, Kadić S, Milunović KP, Pintarić I, Jukić M, Furlan D. Flexible intramedullary nailing for treatment of proximal humeral and humeral shaft fractures in children: a retrospective series of 118 cases. *Orthop Traumatol Surg Res* 2017; 103(5): 765-770.
 9. Pogorelić Z, Furlan D, Biocić M, Mestrović J, Jurić I, Todorić D. Titanium intramedullary nailing for treatment of simple bone cysts of the long bones in children. *Scott Med J* 2010; 55(3): 35-38.
 10. Wall EJ, Jain V, Vora V, Mehlman CT, Crawford AH. Complications of titanium and stainless steel elastic nail fixation of pediatric femoral fractures. *J Bone Jt Surg Am* 2008; 90(6): 1305-1313.
 11. Furlan D, Pogorelić Z, Biočić M, et al. Elastic stable intramedullary nailing for pediatric long bone fractures: experience with 175 fractures. *Scand J Surg* 2011; 100(3): 208-215.
 12. Bong MR, Koval KJ, Egol KA. The history of intramedullary nailing. *Bull NYU Hosp Jt Dis* 2006; 64(3-4): 94-97.
 13. Matityahu A, Eglseder WA Jr. Locking flexible nails for diaphyseal humeral fractures in the multiply injured patient: a preliminary study. *Tech Hand Up Extrem Surg* 2011; 15(3): 172-176.
 14. Stannard JP, Harris HW, McGwin G Jr, Volgas DA, Alonso JE. Intramedullary nailing of humeral shaft fractures with a locking flexible nail. *J Bone Joint Surg Am* 2003; 85(11): 2103-2110.
 15. Zatti G, Teli M, Ferrario A, Cherubino P. Treatment of closed humeral shaft fractures with intramedullary elastic nails. *J Trauma* 1998; 45(6): 1046-1050.
 16. Hall RF, Pankovich AM. Ender nailing of acute fractures of the humerus. A study of closed fixation by intramedullary nails without reaming. *J Bone Joint Surg Am* 1987; 69(4): 558-567.
 17. Shazar N, Brumback RJ, Vanco B. Treatment of humeral fractures by closed reduction and retrograde intramedullary ender nails. *Orthopedics* 1998; 21(6): 641-646.
 18. Verma A, Kushwaha SS, Khan YA, Mohammed F, Shekhar S, Goyal A. Clinical outcome of treatment of diaphyseal fractures of humerus treated by titanium elastic nails in adult age group. *J Clin Diagn Res* 2017; 11(5): RC01-RC04.
 19. Modi D, Patel RR, Solanki RR, Mandaliya M, Chaudhary A. Comparison of results of intramedullary nailing with plate osteosynthesis in the treatment of fracture shaft of humerus. *IJSR* 2014; 3(8): 277-279.
 20. Kim JH, Kang HG, Kim JR, Lin P, Kim HS. Minimally invasive surgery of humeral metastasis using flexible nails and cement in high-risk patients with advanced cancer. *Surg Oncol* 2011; 20(1): e32-e37.
 21. Kaiser MM, Stratmann C, Zachert G, et al. Modification of elastic stable intramedullary nailing with a 3rd nail in a femoral spiral fracture model: results of biomechanical testing and a prospective clinical study. *BMC Musculoskelet Disord* 2014; 15: 3.
 22. Frigg A, Rillmann P, Perren T, Gerber M, Ryf C. Intramedullary nailing of clavicular midshaft fractures with the titanium elastic nail problems and complications. *Am J Sports Med* 2009; 37(2): 352-359.
 23. Fu B. Minimally invasive intramedullary nailing of clavicular fractures by a new titanium elastic nail. *AOTT* 2016; 50(5): 494-500.
 24. Kedzierski M., Król R. Treatment of osteoporotic petrochanteric fractures with use of elastic Ender nails in aged people. *Ortop Traumatol Rehabil* 2002; 4(2): 144-150.
 25. Ando K, Yamaji T. Ender nailing for tibial shaft fractures. *J Orthop Sci* 2000; 5(3): 217-222.
 26. Khurana A, Pendse A, Modi H, Diwanji S, Mathur H, Daveshwar R. Retrograde Ender nailing for humerus shaft fractures. *Acta Orthop Belg* 2009; 75(5): 599-605.
 27. Wang Q, Xu HG, Zhang YC, Dong LJ. Elastic nails for fibular fracture in adult tibiofibular fractures. *Int J Clin Exp Med* 2015; 8(6): 10086-10090.
 28. Sandmann GH, Crönlein M, Neumaier M, et al. Reduction and stabilization of radial neck fractures by intramedullary pinning: a technique not only for children. *Eur J Med Res* 2016; 21: 15.
 29. Gadegone W, Lokhande V, Salphale Y. Screw elastic intramedullary nail for the management of adult forearm fractures. *Indian J Orthop* 2012; 46(1): 65-70.
 30. Huang YC, Renn JH, Tarng YW. The titanium elastic nail serves as an alternative treatment for adult proximal radial shaft fractures: a cohort study. *J Orthop Surg Res* 2018; 13(1): 10.
-
- Received: 13 March 2019
Accepted: 15 April 2019
Correspondence:
Alessio Pedrazzini
Orthopaedic Unit, Oglio Po Hospital
Via Staffolo 51 - 26041 Vicomosciano (CR), Italy
E-mail: alessio.pedrazzini@asst-cremona.it