

Combined radius addition osteotomy and ulnar shortening to correct extra-articular distal radius fracture malunion with severe radial deviation and ulnar plus

Augusto Marcuzzi¹, Debora Lana², Onofrio Laselva³, Francesco Pogliacomì⁴, Massimiliano Leigheb^{5}, Roberto Adani^{1*}*

¹ Department of Hand Surgery, “Policlinico di Modena” University Hospital, Modena, Italy; ² Specialization School in Orthopaedics and Traumatology, University of Modena and Reggio Emilia, Modena, Italy; ³ Department of Orthopaedics and Traumatology, “Policlinico di Modena” University Hospital, Modena, Italy; ⁴ Orthopaedic Clinic, Department of Medicine and Surgery, University Hospital of Parma, Parma, Italy; ⁵ Orthopaedics and Traumatology Unit, Department of Health Sciences, “Maggiore della carità.” Hospital, Università del Piemonte Orientale (UPO), Novara, Italy

Summary. Malunion can occur in 11 to 28% of Distal Radius Fractures and can result in radius shortening and ulnar plus with wrist deviation, pain and disability. We aimed to report particular cases of extra-articular distal radius fracture malunion with severe radial deviation and ulnar plus treated by corrective osteotomy of distal radius with bone graft associated to ulnar procedure. One of these patients was firstly operated with ulna subtraction osteotomy synthesized with plate and in a second stage with distal radius corrective addition osteotomy with homologous bone graft, plate and external fixator. Two other cases were treated in a single-step by radius addition osteotomy and caput ulnae Darrach resection. These three patients were followed-up from 2 to 12 years, successfully observing the maintenance of anatomical correction and recovery of ROM and strength with good pain relief and return to daily activities. After Darrach procedure external-fixation wasn't needed and pronation-supination was better. Darrach procedure can solve ulna plus and improve ROM in pronation-supination with a quicker healing, avoiding the risk of ulnar non-union. Darrach's procedure associated to addition corrective osteotomy of distal radius can be a valid treatment for distal radius severe malunion, in patients with low-moderate functional demand. In conclusion, the surgeon should choose the right corrective treatment after the complete evaluation of the patient and his functional needs. (www.actabiomedica.it)

Key words: distal radius, malunion, osteotomy, Darrach, bone graft, ulna plus, ulnar shortening

Introduction

Distal Radius Fracture (DRF) represents one of the most frequent fractures, accounting for up to 18% of all fractures in elderly (1). Malunion occurs in approximately 23% to 28% of conservatively treated and 11% of surgically treated DRF (2). Malunion can be intra- or extra-articular. Extra-articular malunion is characterized by the alteration of the radiographic parameters as shown by Graham: in sagittal plane lesser volar tilt or

dorsal angulation and in coronal plane lesser ulnar tilt or radial deviation of the radius, often complicated with a shortening of the radius with augmented radio-ulnar variance resulting in instability of the Distal Radio-Ulnar Joint (DRUJ) (3). Lesions of the Triangular Fibrocartilage Complex (TFCC) could be associated.

The decision whether to and how to correct malunion is primarily based on age and functional demand of the patient and secondly on the level of functional impairment and wrist pain (2, 4, 5).

* Authors contributed equally

The goals of surgical correction are to re-establish pre-existent anatomy of the wrist, abolish pain and regain functionality, since these last two aspects are those that most influence the Quality of Life of patients (6).

We aim to report about the clinical and radiographical results obtained in three cases treated by corrective osteotomy of distal radius with bone graft associated to ulnar procedure.

Cases report

We report about three cases of extra-articular DRF complicated by malunion with severe anatomic deformation, treated at our Hand operative Unit between 2006 and 2016.

This study was conducted in accordance with the principles of Declaration of Helsinki. All patients signed informed consent about the treatment they were subjected and the processing of their personal data.

Case 1 (Figg. 1-6)

The first case concerned a 59-years-old pianist with a bad outcome of his right DRF conservatively treated elsewhere two years before. He presented a severe deformity with radial deviation, reduced Range of Motion (ROM) with flexion=10°, extension=15°, pronation=45°, supination=0°, reduced grip force (Jamar=14.8 Kg) and pain at the ulna-carpal joint (VAS=7). The X-ray highlighted a vicious consolidation of the radius and a plus of the ulna.

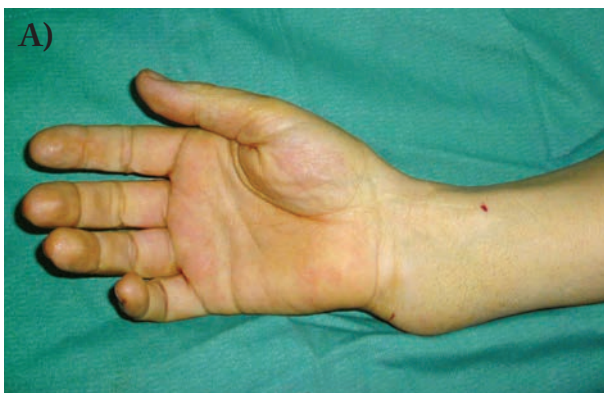

Figure 1 (Case 1). A) Clinical preop volar view; B) Clinical preop dorsal view

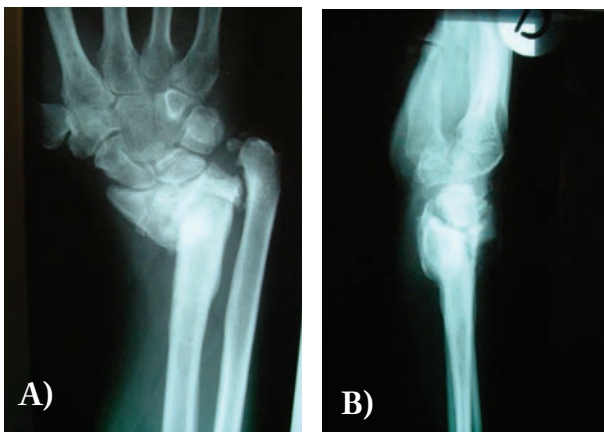
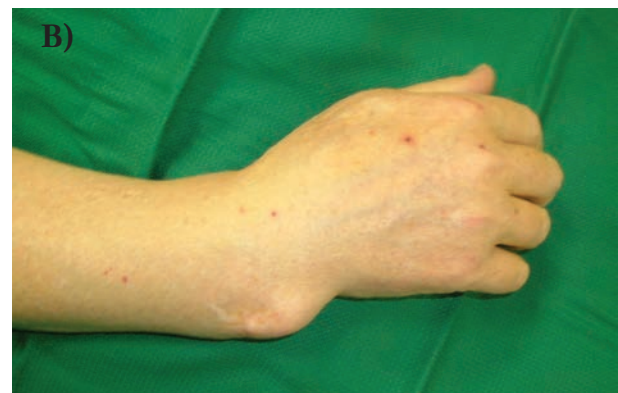

Figure 2 (Case 1). A) Preop AP view X-ray; B) Preop LL view X-ray

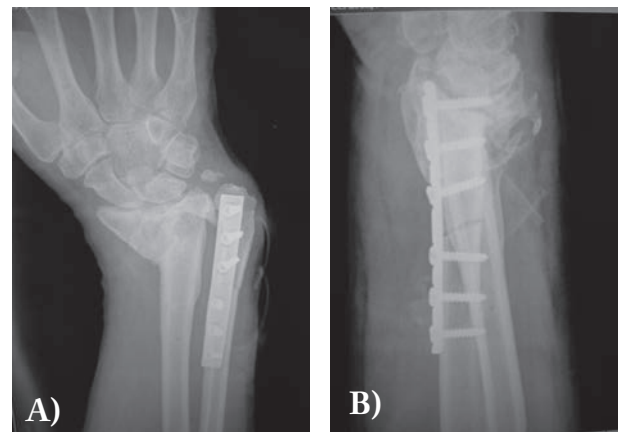


Figure 3 (Case 1). A) AP view X-ray post ulnar shortening; B) LL view X-ray post ulna shortening

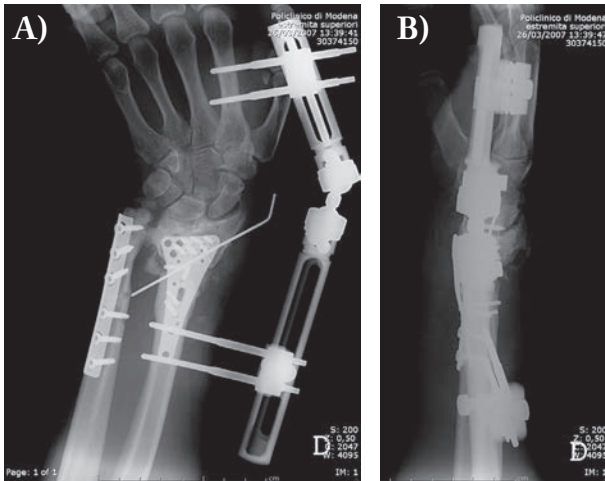


Figure 4 (Case 1). A) AP view X-ray post radius osteotomy with graft; B) LL view X-ray post radius osteotomy with graft

He firstly underwent subtractive osteotomy of the distal ulna and a new synthesis with plate and screws.

One year after, he underwent an open wedge corrective osteotomy of the radius with bone graft from iliac crest, a new osteo-synthesis with angular stabilizer plate and temporary stabilization with Hofmann

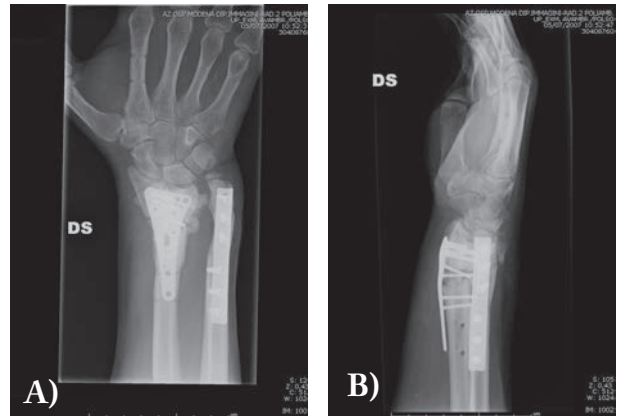
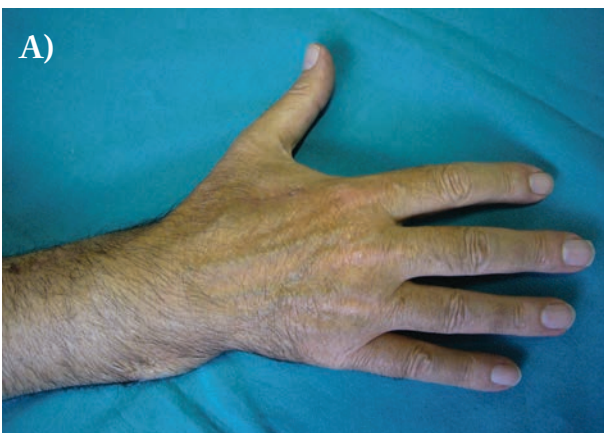

Figure 6 (Case 1): A) AP view X-ray 4 months post 2nd operation; B) LL view X-ray 4 months post 2nd operation

External Fixation System. He was clinically and radiologically followed-up at 1, 6 and 12 months and checked again after 12 years: the correction of deformities was maintained, with optimal aesthetic appearance of the hand. X-ray evidenced a good consolidation of the graft (Figg. 1-6).

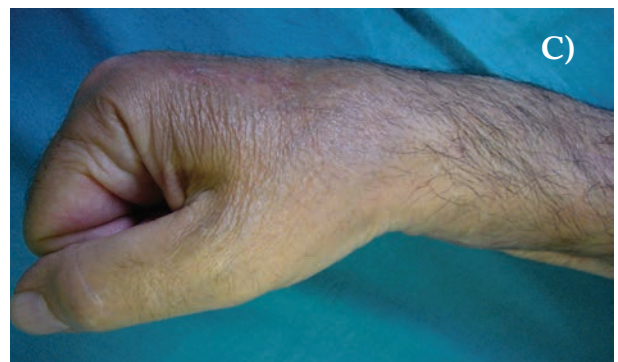
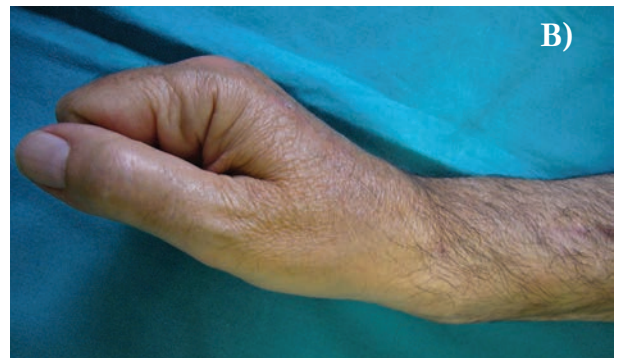
Figure 5 (Case 1): A) Clinical dorsal view 3 months post 2nd operation; B) Clinical lateral view in extension 3 months post 2nd operation; C) Clinical lateral view in flexion 3 months post 2nd operation

Table 1. Clinical outcomes of case 1

	PRE-correction	POST-correction
Flexion (°)	10	45
Extension (°)	15	60
Pronation (°)	45	85
Supination (°)	0	45
Grip Strength (Kg, Jamar)	14.8	18.9
Pain (VAS)	7	0

In this first case we observed (Tab. 1) improvement of wrist mobility (flexion=45°, extension=60°, pronation=85°, supination=45°), restoration of grip strength up to 18.9 Kg (Jamar) from 14.8 Kg and relief from pain (VAS=0, from 7).

Case 2 (Fig. 7)

The second case regarded a 75 years-old housewife who fractured her left distal radius and was conservatively treated elsewhere. She showed up at our attention presenting a severe deformity of the wrist, plus of the ulnar head, functional impairment (flexion 25°, extension 20°, pronation 60°, supination 40°) and exposition with infection of subcutaneous tissues, caused by decubitus of caput ulnae. X-ray showed malunion of the radius fracture with radial and dorsal angulation. She complained severe pain (VAS=6) and reduced grip strength (6.4 kg by Jamar).

The priority was given to the infection's treatment. Afterwards, the patient underwent a single stage corrective surgery including caput ulnae Darrach resection, distal radio-ulnar stabilization using one half of the Extensor Carpi Ulnaris (ECU) tendon, distal radius malunion reclamation with restoration of radius length by a spongy-cortical bone graft from iliac crest and a new osteosynthesis with plate. At 18 months of follow-up we observed a restoration of the ROM and pain relief maintained up to the last check after 3 years (Fig. 7).

This second patient (Tab. 2) achieved a good recovery of ROM with 40° of flexion, 65° extension, 80° pronation, 85° supination, improvement of grip strength up to 12.5 kg (Jamar) from 6.4 Kg and relief from pain (VAS=0, from 6).

Case 3 (Fig. 8-10)

The last case affected a 67 years old restaurateur who fractured his left distal radius and was treated elsewhere by percutaneous pinning. Because he complained pain (VAS=8) and residual functional impairment with flexion 20°, extension 15°, pronation 0°, supination 0° and grip strength (Jamar) 4.5 kg, he underwent further exams: a CT scan documented malunion of the radius fracture with lift of the proximal stump and ulnar plus variance. A Leukoscan Total Body Scintigraphy pointed out an hyperactivity of the radiocompound in the site of the previous fracture and on the left carpal bones, suspicious for overlapping infection.

The extemporaneous histological examination excluded infection (less than 5 PMNs for field) and so this third patient was treated in the same way as the second one.

The patient was clinically and radiologically followed-up at 1, 6, 12 and 24 months post-op. (Figg. 8-10).

In this third case we observed (Tab. 3) a restoration of 60° in flexion, 50° in extension and 85° for both pronation and supination, improvement of grip strength up to 9.2 kg (Jamar) from 4.5 Kg, and pain relief (VAS=2, from 8).

In all the treated patients anatomy and function of the wrist have been restored with a mean gain of flexion of 30°, 42° for extension, 55° for pronation and 58° for supination; mean grip strength was improved of 5.0 kg and mean pain reduced of 6.3 VAS points.

Discussion

Malunion, or vicious consolidation, is a possible complication of DRF, mostly after conservative treatment of displaced unstable fractures (2). Clinically it can result in wrist deformity, rigidity with reduced ROM, pain and reduced force. Severe deformity of distal radius associated to ulnar plus is disabling and may need surgical correction. Restoring the normal alignment and articular congruity is important in order to obtain good functional results (7). Aim of the surgi-

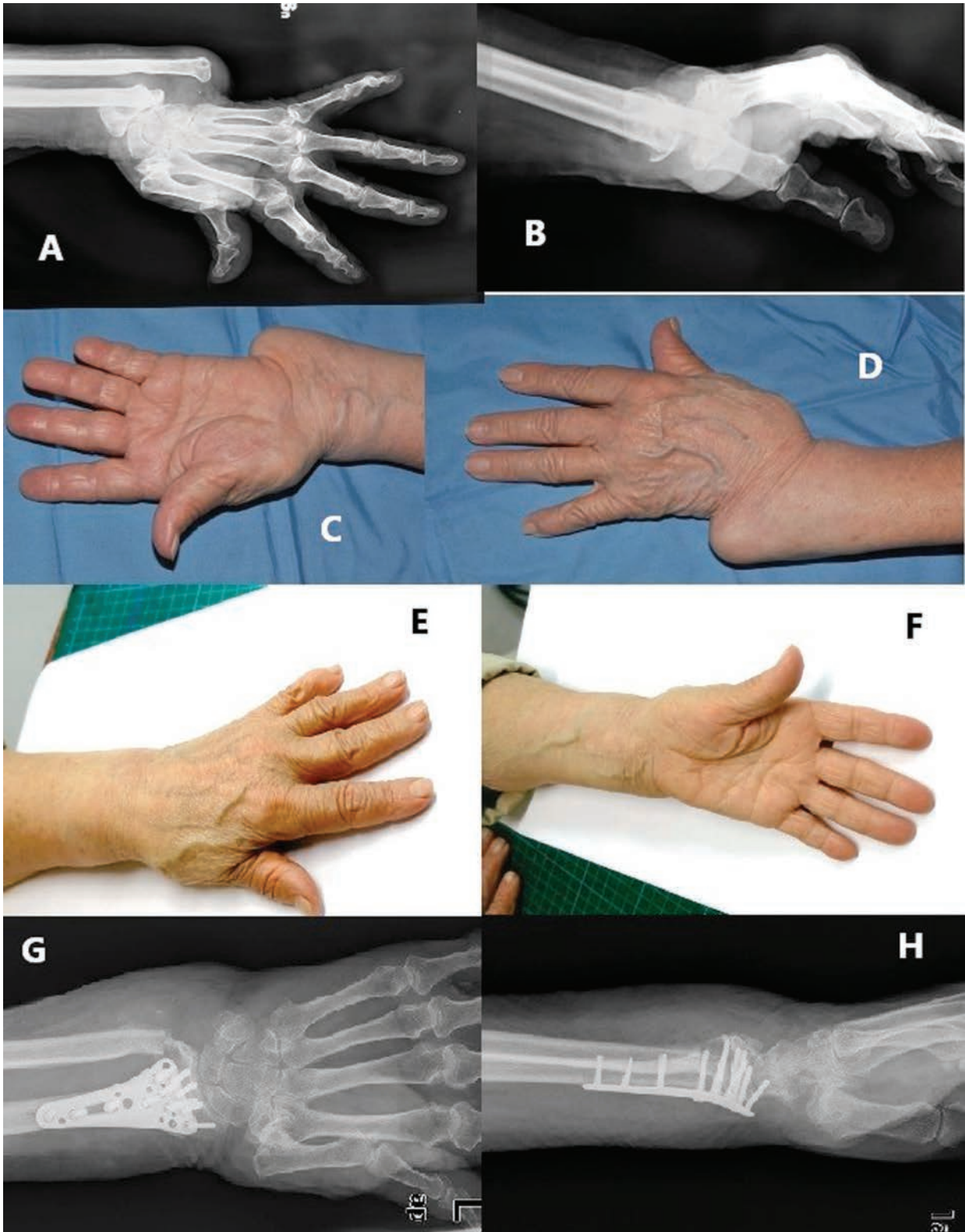


Figure 7 (Case 2): A,B,C,D) Severe wrist deformity with radial deviation and plus of the ulna; A) A/P X-ray; B) L/L X-ray; C) clinical palmar view; D) dorsal view. E,F,G,H) Result 6 months after corrective surgery with Darrach procedure and distal radius addition corrective osteotomy; E) clinical dorsal view; F) palmar view; G) A/P X-ray with plate; H) L/L X-ray with plate

Table 2. Clinical outcomes of case 2

	PRE-correction	POST-correction
Flexion (°)	25	40
Extension (°)	20	65
Pronation (°)	60	80
Supination (°)	40	85
Grip Strength (Kg, Jamar)	6.4	12.5
Pain (VAS)	6	0

cal treatment is to correct deformity in order to restore function with an adequate ROM and strength and relief of pain to ameliorate Quality of Life (8). Ultimately reducing discomfort improves patient satisfaction (9).

There are different surgical options: the most reported is the association of radial corrective osteotomy with ulnar shortening osteotomy (4,10,11). The latter offers the advantage to re-establish the articular congruity respecting the DRUJ, but on the other hand needs a new synthesis which requires a longer time of healing and could result in non-union. This risk is not contemplated for Darrach's procedure, which avoids temporary stabilization; nevertheless, this procedure is not free of complications: in fact it can cause DRUJ instability (12).

Despite treated in different ways, all the three patients reached satisfactory results. In particular we treated the first patient in two times and shortening ulna in order to respect the DRUJ, but, up to date, due

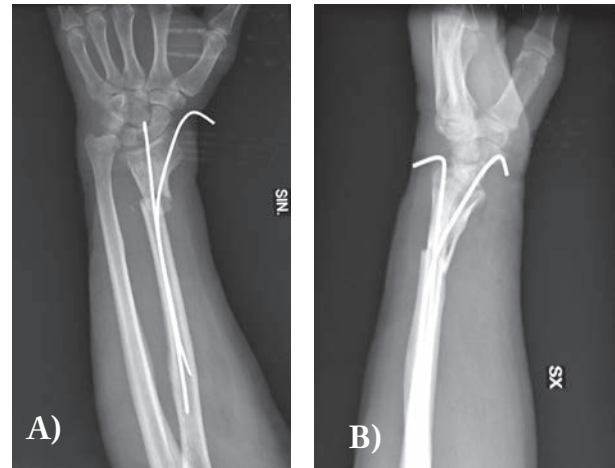
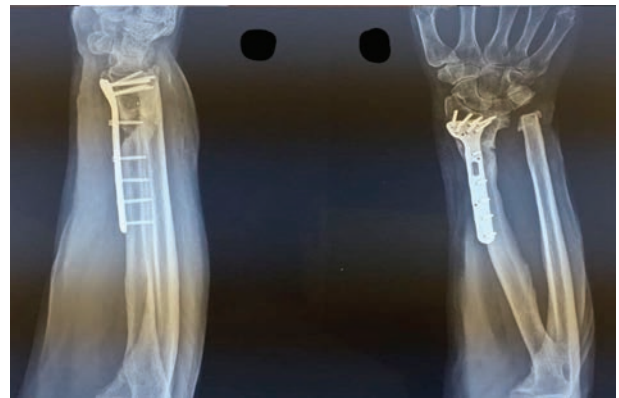
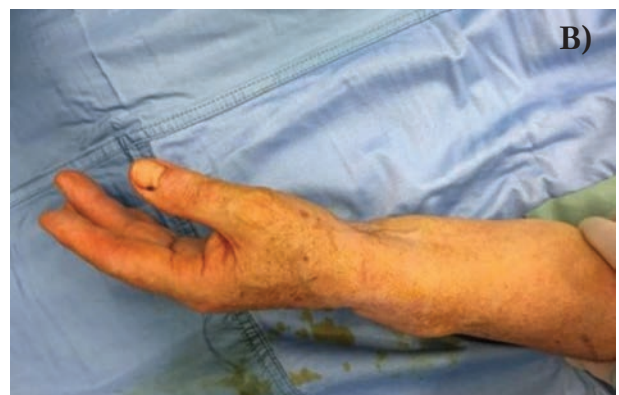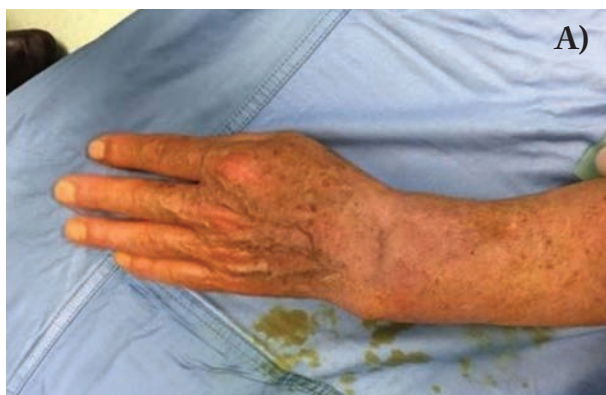
**Figure 9 (Case 3).** A) Preop AP X-ray; B) 3b Preop. LL X-ray**Figure 10 (Case 3).** 3 months post-op X-ray.**Figure 8 (Case 3):** A) Preop. clinical dorsal view; B) Preop. clinical lateral view

Table 3. Clinical outcomes of case 3

	PRE-correction	POST-correction
Flexion (°)	20	60
Extension (°)	15	50
Pronation (°)	0	85
Supination (°)	0	85
Grip Strength (Kg, Jamar)	4.5	9.2
Pain (VAS)	8	2

to our good outcomes, we would treat him in the same way as the other two patients, with radius corrective osteotomy, homologous bone graft, new synthesis with plate and Darrach ulnar procedure, with the advantage of a good and quick recovery of pronation-supination in a single surgical time.

We can say that Darrach's procedure, if opportunely stabilized, associated to addition corrective osteotomy of distal radius, can be a valid treatment for distal radius malunion with severe deformity, in selected patients with low to moderate functional demand. Ulnar shortening osteotomy remains the first treatment option in younger and highly demanding people, because more conservative towards the DRUJ. In conclusion, the surgeon should choose the right corrective treatment after the complete evaluation of the patient and his functional needs.

Conflict of interest: Each author declares that he or she has no commercial associations (e.g. consultancies, stock ownership, equity interest, patent/licensing arrangement etc.) that might pose a conflict of interest in connection with the submitted article

References

- Nellans KW, Kowalskii E, Chung KC. The epidemiology of distal radius fractures. *Hand Clin.* 2012;28(2):113-25.
- Lauri G. Pseudoartrosi del radio distale. *Riv Chir Mano.* 2012;49(2):110-2.
- Graham TJ. Surgical Correction of Malunited Fractures of the Distal Radius. *J Am Acad Orthop Surg.* 1997;5:270-81.
- Chung KC and Mathew AL. Management of Complications of Distal Radius Fractures. *Hand Clin.* 2015;31(2):205-15.
- Goto K, Naito K, Sugiyama Y et al. Corrective Osteotomy with Autogenous Bone Graft with Callus after Malunion of Distal Radius Fracture. *J Hand Surg Asian Pac.* 2018;23(4):571-6.
- Leigheb M, Bosetti M, De Consoli A, Borroni A, Cannas M, Grassi F. Chondral tissue engineering of the reumatoid knee with collagen matrix autologous chondrocytes implant. *Acta Biomed.* 2017;88 (S4):107-113.
- Stecco A, Arioli R, Buemi F et al. Overcoming metallic artifacts from orthopedic wrist volar plating on a low-field MRI scanner. *Radiol Med.* 2018.
- Marcuzzi A, Leigheb M. Transcapho-perilunate dislocation with palmar extrusion of the scaphoid proximal pole. *Acta Biomed.* 2016;87(S1):127-30.
- Leigheb M, Sabbatini M, Baldrighi M, et al. Prospective analysis of pain and pain management in an emergency department. *Acta Biomed.* 2017;88(S4):19-30.
- Oskam J, Bongers KM, Karthaus AJM, Frima AJ, Klasen HJ. Corrective osteotomy for malunion of the distal radius. *Arch Orthop Trauma Surg.* 1996;115(3-4):219-22.
- Barbaric K, Rujevcan G, Labas M, Delimar D, Bicanic G. Ulnar shortening osteotomy after distal radius fracture malunion: review of literature. *Open Orthop J.* 2015;9:98-106.
- Manjeet S, Siddhartha S, Chetan P et al. Wide resection and stabilization of ulnar stump by extensor carpi ulnaris for giant cell tumor of distal ulna: two case reports. *Cases J.* 2009;2:8617.

Received: 1 October 2019

Accepted: 3 November 2019

Correspondence:

Prof. Massimiliano Leigheb MD, PhD, MSc

S.C. Ortopedia-Traumatologia

AOU "Maggiore della Carità"

Dipartimento di Scienze della Salute

Università del Piemonte Orientale (UPO)

Via Solaroli 17 – 28100 Novara (Italy)

Tel. +39 0321-3733460

Fax +39 0321-393691

E-mail: massimiliano.leigheb@med.uniupo.it