

Treatment of haemorrhoidal disease with micronized purified flavonoid fraction and sucralfate ointment

Antonino Amaturò, Massimo Meucci, Francesco Saverio Mari

Casa di Cura Siligato, Civitavecchia, Italy

Summary. Hemorrhoidal disease is a very common disease characterized by the presence of a mucous prolapse of the rectum and by varicosis of the hemorrhoidal plexus. Medical therapy is mainly indicated for the treatment of symptoms such as bleeding, pain and itching. The use of the micronized purified flavonoid fraction (MPFF) has proven to be effective in treating symptoms of hemorrhoidal disease. Topical use of sucralfate has shown good results in the reduction of hemorrhoidal pain and itching. Our experience with three cases treated with combined use of MPFF and a topical medical device in the form of rectal ointment, composed by sucralfate and herbal (calendula, witch hazel leaf (hamamelis), chamomile) extracts, has shown good results in terms of pain and itching control and in edema reduction.

Key words: Micronized purified flavonoid fraction (MPFF), topical medical device, rectal ointment composed by sucralfate and other herbal extracts, hemorrhoidal disease, perianal pain, itching

Introduction

Haemorrhoidal disease is a very common anorectal condition defined as the symptomatic enlargement and distal displacement of the normal anal cushions (1). It is clinically characterized by painless rectal bleeding during defecation with or without prolapsing anal tissue (1-3).

In absence of rectal prolapse the medical therapy is always recommended as first step. Surgery is indicated for high-graded internal hemorrhoids, or when non-operative approaches have failed, or complications have occurred (1-4).

Constipation and abnormal bowel habits (e.g., straining, prolonged sitting, and frequent bowel movements) can play a significant role in patients with symptomatic hemorrhoids.

For these reasons dietary modification and precaution in toilet behavior represents the first approach to haemorrhoidal disease. Medical therapy plays an important role in the treatment of hemorrhoidal disease (2-5). Over the years, numerous drugs have been proposed both orally and as topical ointments.

Numerous studies have shown the efficacy of phlebotonics in the treatment of hemorrhoidal disease symptoms (2-6). The availability of a new topical medical device in the form of rectal ointment composed by sucralfate and herbal (calendula, witch hazel leaf (hamamelis), chamomile) extracts, was an opportunity to evaluate the effectiveness of the combined therapy of MPFF tablets and the topical rectal ointment in three patients who came to our attention for II-III degree hemorrhoidal disease according to Goligher classification.

Therapy

The main goal of medical treatment is to control acute symptoms of hemorrhoids rather than to cure the underlying hemorrhoids. There are several modern drugs and traditional medicine used which are available in a variety of format including pill, suppository, cream and wipes. However, the published literature lacks strong evidence supporting the true efficacy of topical treatment for symptomatic hemorrhoids.

MPFF is one of the most common oral phlebotonic drug used for treating hemorrhoids. It is apparent that flavonoids could increase vascular tone, reduce venous capacity, decrease capillary permeability, facilitate lymphatic drainage and has anti-inflammatory effects (4-6). Sucralfate is the aluminium hydroxide salt of the disaccharide sucrose octasulfate. For more than three decades, sucralfate has been used as a cytoprotective agent for treatment of gastrointestinal ulcer diseases. This salt has antimicrobial and antioxidant activity, stimulates the secretion of prostaglandin E2 (PGE2) and subsequent increased blood flow and mucus formation, and enhances the production of epidermal growth factor (EGF) which can lead to increased angiogenesis (7-8).

In the three clinical cases here reported it has been used a combo treatment of MPFF in tablets and a topical medical device in the form of rectal ointment, composed by sucralfate and herbal extracts. After three weeks, it has been evaluated the result in terms of pain, itching control, edema reduction. Moreover patient's perception of symptoms healing has been assessed with a satisfaction score from 0 to 5.

Clinical Cases

Case 1

40-year-old female who came to our attention for the presence of III degree mucohemorrhoidal prolapse. In anamnesis 2 natural births, no significant pathology. The symptomatic picture was characterized by perianal pain and rectorrhagia. Itching was also experienced. On objective examination, presence of III degree mucohemorrhoidal prolapse associated with thrombosis of the hemorrhoidal plexus at 11 o'clock.

The patient was treated for 3 weeks with oral assumption of MPFF 500 mg twice daily and topical application of rectal ointment composed by sucralfate and herbal extracts twice daily.

Pain and edema progressively decreased in the first 2 weeks and disappeared in the third week (See Figure 1). Patient perception of symptoms healing assessed with a satisfaction score from 0 to 5 showed a good perception of this patients with a score of 4.

Case 2

58-year-old female who underwent to office visit for the presence of III degree mucohemorrhoidal prolapse. In anamnesis 1 natural birth, arterial hypertension, type II diabetes and umbilical hernia. The patient had previously undergone appendectomy and cholecystectomy. She suffered from constipation, rectal bleeding and pain. Rectal exam showed a III degree mucohemorrhoidal prolapse associated to hyperemia and edema of the internal hemorrhoidal plexus. She was treated for 3 weeks with oral assumption of MPFF 500 mg twice daily and topical application of rectal ointment composed by sucralfate and herbal extracts twice daily. After 3 weeks of the combo therapy we observed a complete resolution of the hyperemia with a reduced incidence of rectal bleeding and the disappearance of pain, a significant reduction of edema and even itching was reduced (see figure 2). This patient also showed a good perception of symptoms healing with a satisfaction score of 5.

Case 3

47-year-old male who came to our attention for the presence of II-III degree mucohemorrhoidal prolapse. In anamnesis appendectomy, splenectomy and no other significant pathology. The symptoms were rectorrhagia, pain and itching. On objective examination, presence of II-III degree mucohemorrhoidal prolapse with generalized edema of the mucosa. The therapy was conducted for 3 weeks with oral assumption of MPFF 500 mg twice daily and topical application of rectal ointment composed by sucralfate and herbal

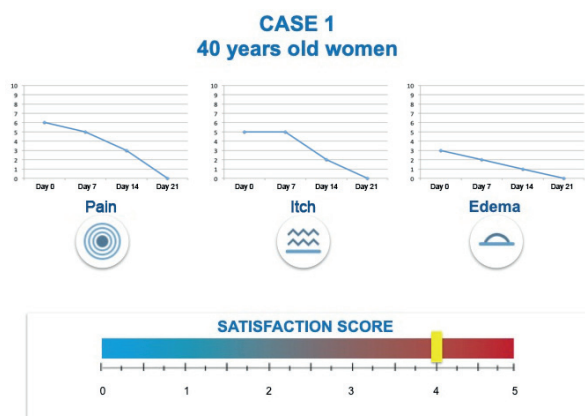


Figure 1.

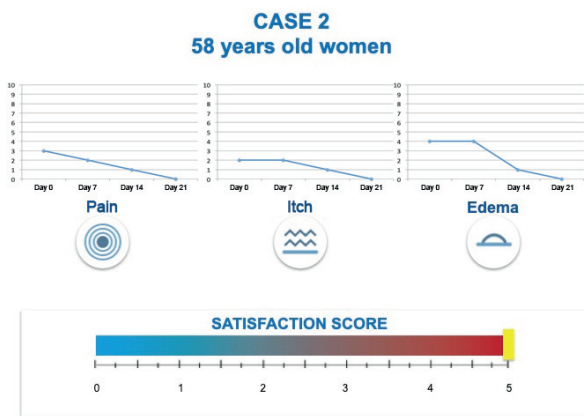


Figure 2.

extracts twice daily. After three weeks we assisted to a progressive resolution of the pain and itching and to a reduction of the edema (see Figure 3). Patient satisfaction score at the end of the combo therapy was 4.

Conclusion

Haemorrhoidal disease is the cause of most proctologic complaints and hundreds of medical and surgical therapies have been proposed to relieve symptoms. However, the role and the correct indication of medical treatments are still controversial and rarely supported by adequate trials, but in our experience the combined use of MPFF and topical application of a medical device in the form of rectal ointment composed by sucralfate and herbal extracts, seems to have a benefic effect in terms of hemorrhoidal disease symptoms control.

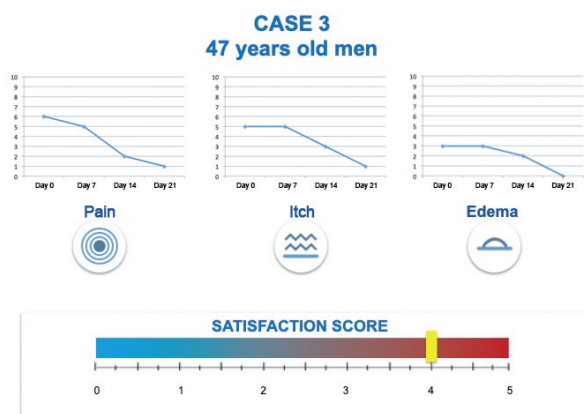


Figure 3.

Conflict of interest: Meucci and Mari declare that they have no commercial associations (e.g. consultancies, stock ownership, equity interest, patent/licensing arrangement etc.) that might pose a conflict of interest in connection with the submitted article. Amaturò declare that he has commercial associations with Servier Italia.

Reference

1. Lohsirivat V. Hemorrhoids: from basic pathophysiology to clinical management. *World J Gastroenterol.* 2012;18(17):2009-17.
2. Perera N, Liolitsa D, Iype S, et al. Phlebotonics for haemorrhoids. *Cochrane Database Syst Rev.* 2012;(8):CD004322.
3. van Tol RR, Kleijnen J, Watson AJM, et al. European Society of ColoProctology: guideline for haemorrhoidal disease. *Colorectal Dis.* 2020 Feb 17[Online ahead of print].
4. Gallo G, Martellucci J, Sturiale A, et al. Consensus statement of the Italian society of colorectal surgery (SICCR): management and treatment of hemorrhoidal disease. *Tech Coloproctol.* 2020;24(2):145-164.
5. Aziz Z, Huin WK, Badrul Hisham MD, et al. Efficacy and tolerability of micronized purified flavonoid fractions (MPFF) for haemorrhoids: A systematic review and meta-analysis. *Complement Ther Med.* 2018;39:49-55.
6. Caetano AC, Cunha C, Arroja B, et al. Role of a Micronized Purified Flavonoid Fraction as an Adjuvant Treatment to Rubber Band Ligation for the Treatment of Patients With Hemorrhoidal Disease: A Longitudinal Cohort Study. *Ann Coloproctol.* 2019;35(6):306-312.
7. Alvandipour M, Ala S, Tavakoli H, et al. Efficacy of 10% sucralfate ointment after anal fistulotomy: A prospective, double-blind, randomized, placebo-controlled trial. *Int J Surg.* 2016;36(Pt A):13-17.
8. Gupta PJ, Heda PS, Kalaskar S, et al. Topical sucralfate decreases pain after hemorrhoidectomy and improves healing: a randomized, blinded, controlled study. *Dis Colon Rectum.* 2008 Feb;51(2):231-4.

Received: 29 January 2020

Accepted: 2 March 2020

Correspondence:

Antonino Amaturò

Casa di cura Siligato

Via, 00053 Civitavecchia, Italy

Tel. +39076623247

Fax: +39076635338

E-mail: a.amaturò@clinicasiligato.it