

SARCOIDOSIS DEVELOPMENT DURING ULCERATIVE COLITIS REMISSION IN A PATIENT WITH A SUSCEPTIBLE HUMAN LEUKOCYTE ANTIGEN SEROTYPE

Toshiyuki Sumi^{1,2}, Gen Yamada², Takafumi Yorozuya², Yusuke Tanaka², Yasumasa Tanaka¹, Yuji Sakuma³, Hiroki Takahashi²

¹Department of Pulmonary Medicine, Steel Memorial Muroran Hospital, Japan; ²Department of Respiratory Medicine and Allergology, Sapporo Medical University School of Medicine, Sapporo, Japan; ³Department of Molecular Medicine, Research Institute for Frontier Medicine, Sapporo Medical University School of Medicine, Sapporo, Japan

ABSTRACT. The combination of sarcoidosis and ulcerative colitis (UC) is very rare, and its pathogenesis remains unknown. Hereditary factors as well as environmental factors have been speculated, including an association with the human leucocyte antigen (HLA) genotype. A 62-year-old Japanese woman with UC presented with complaint of a cough. Abnormal shadows were evident on the chest X-ray during mesalazine therapy. Multiple indolent subcutaneous nodules were also detected. Transbronchial lung and skin biopsies showed non-caseous epithelioid granulomas, which were pathologically compatible with sarcoidosis. After steroid therapy, she became asymptomatic and the abnormal shadows and subcutaneous nodules disappeared. HLA serological typing revealed that she harbored the sarcoidosis-related HLA-DR14 allele, as well as UC-related HLA-B52 and HLA-DR15 alleles. This case suggests that a susceptible HLA genotype may influence the onset of the combination of sarcoidosis and UC.

KEY WORDS: Human leukocyte antigen, Inflammatory bowel disease, Sarcoidosis, Ulcerative colitis

INTRODUCTION

Sarcoidosis is a systemic granulomatous disorder characterized by the infiltration of activated lymphocytes, mainly in the lungs, skin, and lymph nodes. Ulcerative colitis (UC) is a relapsing non-transmural inflammatory bowel disease that mainly affects the large intestine. Although both diseases are associated with specific HLA subtypes, environmental factors are also important in their onset (1, 2). To date, there have been 24 reported cases of the combination of

both diseases in the same patient (3-18). However, the underlying mechanisms of comorbidity are almost completely unknown. Herein we report on a UC patient who developed sarcoidosis and whose HLA subtype was examined by serological typing.

CASE REPORT

A 62-year-old Japanese woman with UC was referred to our hospital complaining of a dry cough and exhibited abnormal shadows in a chest X-ray. She had developed UC when she was 38 years old and had suffered from it for 17 years before going into remission for 7 years, after being treated with mesalazine at the age of 55 years. She had no history of smoking. Her prior medical history showed no evidence of pulmonary diseases.

On admission, there were indolent elastic hard subcutaneous nodules in her hip, forearms, and legs. The laboratory findings are shown in Table 1.

Received: 29 August 2017

Accepted after revision: 21 February 2021

Correspondence: Toshiyuki Sumi
Department of Respiratory Medicine and Allergology,
Sapporo Medical University School of Medicine,
South 1, West 17, Chuo-ku, Sapporo 060-8556, Japan.
Tel: +81-11-611-2111
Fax: +81-11-611-2136
E-mail: tsumi@sapmed.ac.jp

Table 1. Laboratory data on admission. Laboratory data showed that angiotensin converting enzyme, lysozyme, and soluble interleukin-2 receptor were elevated. These data indicated sarcoidosis. Human leukocyte antigen (HLA) typing by serology revealed that the patient had the sarcoidosis-related HLA allele DR14 as well as the ulcerative colitis-related HLA alleles B52 and DR15.

Hematology			Biochemistry			Serology		
WBC	5,62	x10 ³ /μL	TP	6,7	g/dL	KL-6	898	U/mL
Neu.	62,6	%	ALb	3,9	g/dL	SP-D	107	ng/mL
Ly.	23,8	%	AST	27	IU	sIL-2R	3520	U/mL
Eo.	5,2	%	ALT	27	IU	ACE	110	U/L
Ba.	0,7	%	LDH	312	IU	Lysozyme	53,9	μg/mL
Mo.	7,7	%	ALP	248	IU	SA-A	13,9	μg/mL
RBC	499	x10 ³ /μL	γ-GTP	22	IU			
Hb	15,5	g/dL	BUN	13,2	mg/dL			
Hct	41,8	%	Cr	0,74	mg/dL			
Plt	203	x10 ³ /μL	Na	142	mEq/dL			
BS	101	mg/dL	K	3,7	mEq/dL			
HbA1c	6,9	%	Cl	106	mEq/dL			
			Ca	9,3	mg/dL			
HLA typing by serology								
haplotype1 (A24, B62, DR14)								
haplotype2 (A26, B52, DR15)								

Legends: KL-6, Krebs von den Lungen-6; SP-D, surfactant protein D; sIL-2R, soluble interleukin-2 receptor; ACE, angiotensin converting enzyme; SA-A, serum amyloid A.

The serum levels of angiotensin converting enzyme (ACE) and lysozyme were elevated to 110 U/L and 53.9 μg/mL, respectively, and serum soluble interleukin-2 receptor was also high (3,520 U/mL). HLA typing by serology revealed haplotype 1 antigens HLA-A24, HLA-B62, and HLA-DR14, and haplotype 2 antigens HLA-A26, HLA-B52, and HLA-DR 15. Interestingly, it has been reported that HLA-DR14 is associated with sarcoidosis, and HLA-B52 and HLA-DR15 are associated with UC.

As shown in Figure 1, chest X-ray showed multiple nodular shadows in bilateral lung fields and right hilar lymphadenopathy. Chest computed tomography (CT) revealed granular and nodular shadows in the entire bilateral fields of the lungs, thickened bronchial walls of bilateral lower lobes, and right hilar and mediastinal lymphadenopathy (Figure 2). Gallium-scintigraphy revealed accumulation in bilateral lungs, right hip, bilateral forearms, bilateral groin, hypogastric subcutaneous nodules, and the lymph nodes in the mediastinum.

Although the findings described above suggested that she had sarcoidosis, we did not completely exclude

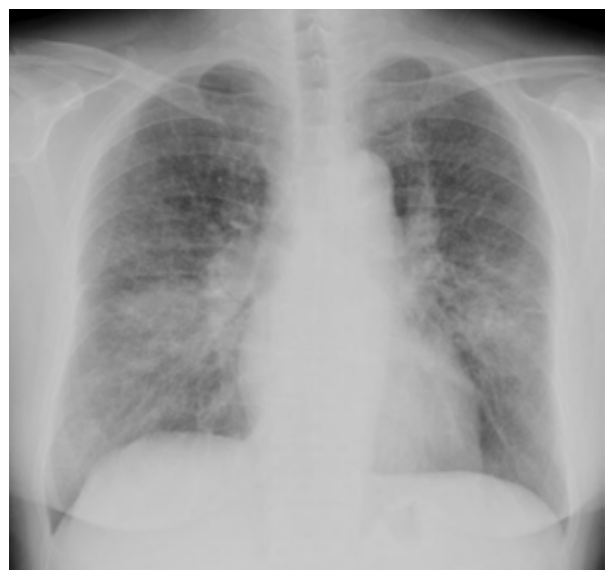

Figure 1. Chest X-ray showing multiple nodular shadows in bilateral lung fields and right hilar lymphadenopathy.

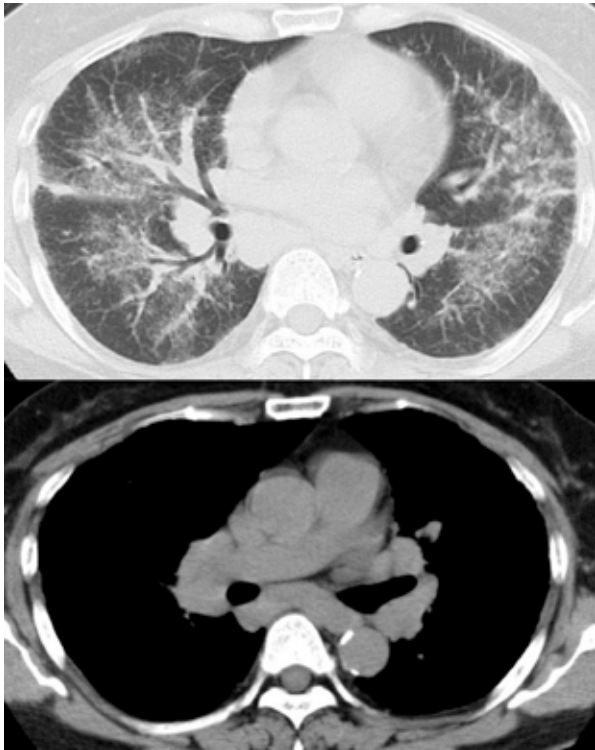


Figure 2. Chest CT showing ground glass opacities with small nodules, bronchial wall thickness in bilateral lung fields, and hilar and mediastinal lymph node swelling.

the possibility that she had pulmonary manifestations of UC or mesalazine-induced pneumonitis. Accordingly, we performed bronchoalveolar lavage (BAL) and examined the tissues of the lung and skin for granuloma to diagnose sarcoidosis. The total cell count in BAL fluid was elevated to 6.0×10^5 cells/mL (histiocytes 51%, lymphocytes 47.5%, neutrophils 1%, eosinophils 0.5%), and the CD4/CD8 ratio was as high as 7.91. Pathological examination of the lung and skin revealed non-caseating granulomas, as expected (Figure 3). We ultimately concluded that the patient had developed sarcoidosis and followed her carefully without steroid therapy.

Unfortunately, her cough gradually worsened. Fourteen months after the diagnosis of sarcoidosis, chest CT showed that a cystic lesion had appeared in the left upper lobe, and granular shadows in bilateral lungs increased steadily in size, resulting in partial consolidation (Figure 4). These findings led us to surmise that her health had deteriorated due to the progression of sarcoidosis, and we began to treat her with 30 mg/day of prednisolone. In response to the steroid therapy, her cough was cured, and the subcutaneous nodules and pulmonary consolidation both disappeared. However, the cystic lesion in the upper left lobe remained apparent on chest CT (Figure 4). We then reduced prednisolone carefully over a period of 6 months, and she has remained alive and well without steroids for over 1 year.

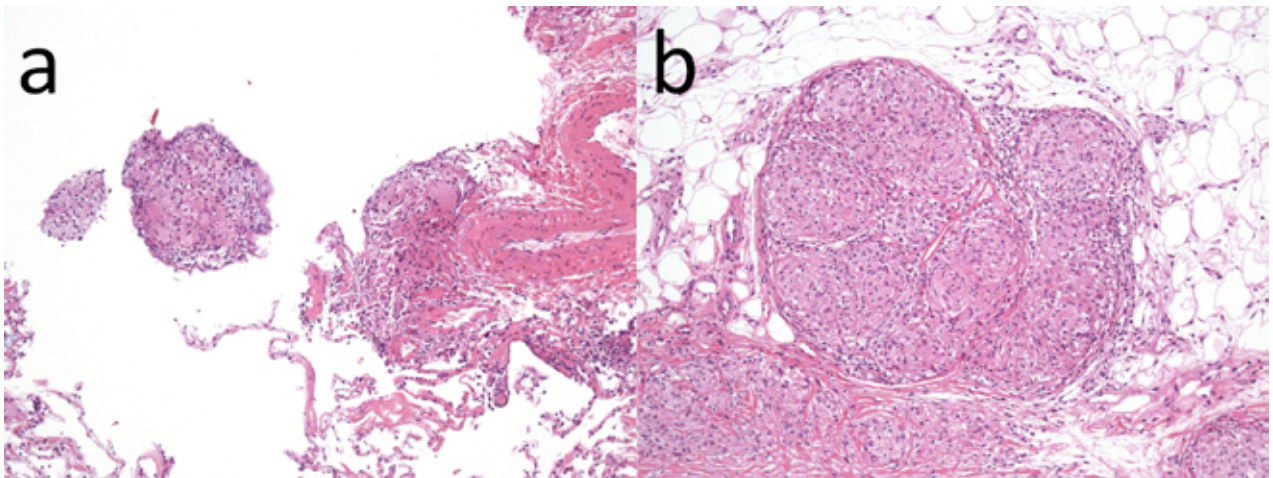


Figure 3. (a) A transbronchial lung biopsy specimen showing multiple non-caseous epithelioid granulomas including polynuclear giant cells around the pulmonary artery branches and bronchial epithelium. (b) Skin biopsy specimen showing multiple non-caseous epithelioid granulomas including polynuclear giant cells in subcutaneous adipose tissue just below the dermis. Magnification 10 \times , hematoxylin and eosin staining.

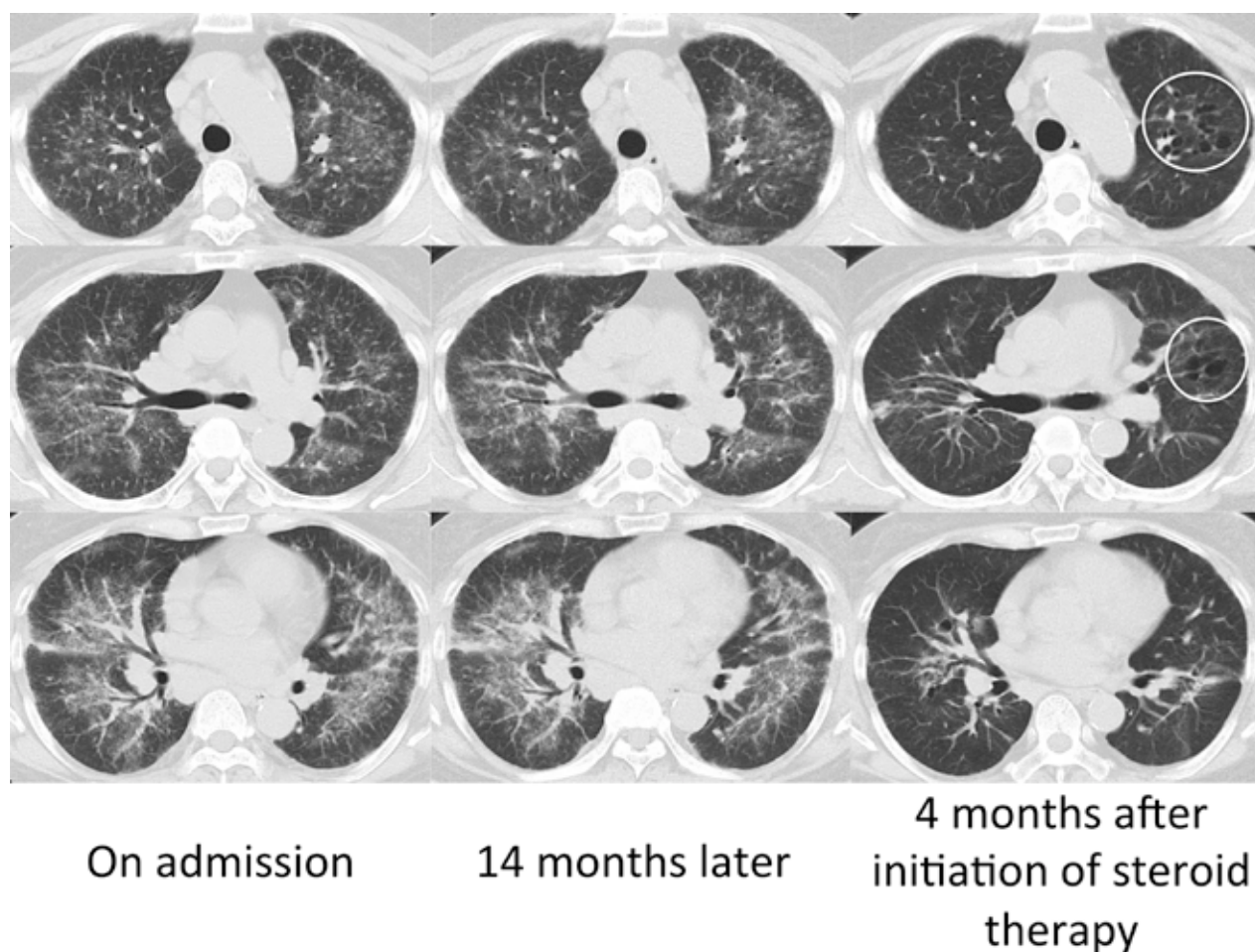


Figure 4. Clinical course of computed tomography (CT) findings. Compared with chest CT findings associated with sarcoidosis on admission, cystic lesions had appeared in the left upper lobe and multiple granular shadows in both lungs had increased 14 months later. Four months after the start of steroid therapy, the granular shadows had almost disappeared, but the left upper lobe cystic lesion (indicated by white circles) remained.

DISCUSSION

To our knowledge, this is the first report of a patient with an HLA serotype associated with sarcoidosis (HLA-DR14) and UC (HLA-B52 and HLA-DR15) who was identified with both conditions. The allele frequencies of the respective antigenic types in the Japanese population are HLA-DR14: 10.01%, HLA-B52: 11.37%, and HLA-DR15: 19.62% (19). Table 2 summarizes 24 reported cases of the combination of sarcoidosis and UC, including the current case. Of the eight patients whose HLA serotype were analyzed (7, 8, 13, 14, 15, and the current report), six had an HLA serotype associated with sarcoidosis while two had an

HLA serotype associated with UC. One report has demonstrated that sarcoidosis is clearly associated with HLA-DRB1*11, DRB1*12, DRB1*14, and DRB1*08 in Japan (20). The present case findings corroborate with this report in that she had HLA-DR14, which is a serotype of HLA-DRB1*14. It is also known that UC is significantly associated with specific HLA genotypes (21). HLA-DRB1*1502 (HLA-DR15) and HLA-B*52 are associated with UC development in Japan, and HLA-DRB1*0103 (HLA-B52) is associated with the disease in Europe and America (22). The present case findings were also consistent with these observations, in that she had HLA-B52 and HLA-DR15, which may have been related to the onset of UC.

Table 2. A summary of cases of sarcoidosis associated with ulcerative colitis (UC) reported from 1967 to 2015. There were 24 patients with both sarcoidosis and UC reported from 1967 to date, including the present case. Of the eight cases whose human leukocyte antigen (HLA) serotypes were analyzed (7, 8, 13, 14, 15, and the present case), six had an HLA allele associated with sarcoidosis, while two had an HLA allele associated with UC.

Case	Year	Age(yr)/sex	Order of onset	Interval of onsets (yr)	HLA	Treatment of preceding diseases (sarcoidosis or UC)	Complications	Reference
1	1967	30/M	UC→SAR	2	N.D.	Steroid	Primary biliary cirrhosis	3
2	1969	26/M	UC→SAR	Autopsy	N.D.	Steroid, salazopyrin, total colectomy		4
3	1971	52/F	SAR→UC	13	N.D.	None		5
4	1981	64/F	Same time	0	N.D.	None		6
5	1986	44/F	UC→SAR	20	Three patients were HLA A1, B8 and DR3 positive.	Steroid	Toxic megacolon	7
6		31/M	Same time	0		None		
7		64/M	SAR→UC	12		Steroid		
8		38/F	SAR→UC	6		None		
9		33/M	SAR→UC	15		Steroid		
10		20/M	UC→SAR	16		Proctocolectomy	Urinary stone	
11		37/F	SAR→UC	9		None		
12		47/F	UC→SAR	13		Proctocolectomy		
13	1987	30/M	UC→SAR	13	HLA B8	Steroid, sulfasalazine	Primary sclerosing cholangitis, bile duct carcinoma	8
14	1989	42/M	UC→SAR	13	N.D.	Symptomatic treatment	Sjogren's syndrome, sclerosing cholangitis	9
15	1995	38/M	UC→SAR	13	N.D.	Steroid, sulfasalazine, proctocolectomy		10
16	1996	41/M	UC→SAR	6	N.D.	Tixocortol		11
17	1996	58/F	UC→SAR	36	N.D.	Steroid, proctocolectomy	Sjogren's syndrome	12
18	1997	22/M	UC→SAR	6	HLA A24, B52, B54, DR2, DR4	None	Insulin-dependent diabetes mellitus	13
19	1999	33/F	Same time	0	HLA DR52	None	Insulin-dependent diabetes mellitus	14
20	2001	38/F	UC→SAR	10	HLA A2, A28, B27, B44	Steroid, sulfasalazine		15
21	2003	53/M	UC→SAR	3	N.D.	Steroid, mesalamine	Appendiceal cancer	16
22	2005	33/F	UC→SAR	10	N.D.	Steroid	Dermatomyositis	17
23	2013	50/M	UC→SAR	8	N.D.	Steroid, salazopyrin		18
24	2015	62/F	UC→SAR	24	HLA A24, A26, B62, B52, DR14, DR15	Mesalazine		Our case

Legends: HLA, human leukocyte antigen; UC, ulcerative colitis; SAR, sarcoidosis; N.D., not described.

It has been reported that the prevalence of sarcoidosis is only 4.7–64.0 per 100,000. However, sarcoidosis seems to develop more frequently in UC patients (1) because it was observed in 8 of 680 UC patients in northern Europe (10). Although this suggests that sarcoidosis is not a rare disease in UC patients, sarcoidosis is not the only disease that affects the lung in UC patients. Extra-intestinal manifestations of UC and mesalazine-induced lung injury need to be differentiated. Pulmonary manifestations of UC include bronchiectasis, necrotizing bronchiolitis, bronchiolitis obliterans, and diffuse panbronchiolitis (23). We need to recognize that the extent of UC-related pulmonary manifestation is not always correlated with the activity of intestinal manifestation (24). On the other hand, mesalazine-induced lung injury has been reported to involve alveolar eosinophilic infiltrates, interstitial lymphocytic infiltrates, alveolar fibrosis, and non-necrotizing granulomas (25). If a patient with UC develops lung involvement during UC treatment, we need to distinguish carefully between lung involvements from extra-intestinal manifestations, mesalazine-induced lung injury, and sarcoidosis.

In conclusion, herein we reported the first case of a patient with an HLA serotype associated with susceptibility to both sarcoidosis and UC and who was identified with both conditions. However, cases of patients suffering from both conditions without susceptible HLA serotypes have also been reported (15). These cases suggest that there might be unknown common factors between sarcoidosis and UC. Further studies should be performed to better understand the associations between sarcoidosis and UC.

Conflicts of interest: None

REFERENCES

- Valeyre D, Prasse A, Nunes H, Uzunhan Y, Brillet PY, Müller-Quernheim J. Sarcoidosis. *Lancet* 2014; 383: 1155-67.
- Danese S, Fiocchi C. Ulcerative colitis. *N Engl J Med* 2011; 365: 1713-25.
- Trujillo NP, Halstead LS, Ticktin HE. Chronic ulcerative colitis, xanthomatous biliary cirrhosis and sarcoidosis. Report of a case. *Med Ann Dist Columbia* 1967; 36: 170-4.
- Jalan KN, MacLean N, Ross JM, Sircus W, Butterworth ST. Carcinoma of the terminal ileum and sarcoidosis in a case of ulcerative colitis. *Gastroenterology* 1969; 56: 583-8.
- Watson DW, Friedman HM, Quigley A. Immunological studies in a patient with ulcerative colitis and sarcoidosis. *Gut* 1971; 12: 541-3.
- Theodoropoulos G, Archimandritis A, Davaris P, Plataris J, Melissinos K. Ulcerative colitis and sarcoidosis: a curious association—report of a case. *Dis Colon Rectum* 1981; 24: 308-10.
- Barr GD, Shale DJ, Jewell DP. Ulcerative colitis and sarcoidosis. *Postgrad Med J* 1986; 62: 341-45.
- Van Steenberghe W, Fevery J, Vandenbrande P, et al. Ulcerative colitis, primary sclerosing cholangitis, bile duct carcinoma, and generalized sarcoidosis. Report of a unique association. *J Clin Gastroenterol* 1987; 9: 574-9.
- Johnson CD. Obstructive jaundice in a patient with ulcerative colitis, Sjögren's syndrome and sarcoidosis. *J R Soc Med* 1989; 82: 362.
- Fries W, Grassi SA, Leone L, et al. Association between inflammatory bowel disease and sarcoidosis. Report of two cases and review of the literature. *Scand J Gastroenterol* 1995; 30: 1221-3.
- Le Gall F, Loeuillet L, Delaval P, Thoreux PH, Desrues B, Ramée MP. Necrotizing sarcoid granulomatosis with and without extrapulmonary involvement. *Pathol Res Pract* 1996; 192: 306-13.
- Cox NH, McCrea JD. A case of Sjögren's syndrome, sarcoidosis, previous ulcerative colitis and gastric autoantibodies. *Br J Dermatol* 1996; 134: 1138-40.
- Yoshioka K, Nishimura S, Kitai S, Kondo M. Association of sarcoidosis, insulin-dependent diabetes mellitus, and ulcerative colitis. *Arch Intern Med* 1997; 157: 465-7.
- Vial B, Chabot F, Antunes L, et al. Association of sarcoidosis and hemorrhagic rectocolitis in an insulin-dependent diabetic. [Article in French] *Rev Mal Respir* 1999; 16: 1151-4.
- Nilubol N, Taub PJ, Venturero M, Lichtiger S, Bauer JJ. Ulcerative colitis and sarcoidosis. *Mt Sinai J Med* 2001; 68: 400-2.
- Vaiphei K, Gupta N, Sinha SK, Nagi B, Singh K. Association of ulcerative colitis with pulmonary sarcoidosis, subcutaneous lipomatosis and appendiceal adenocarcinoma. *Indian J Gastroenterol* 2003; 22: 193-4.
- Hayashi T, Nakamura T, Kurachi K, et al. Ulcerative colitis accompanied with sarcoidosis and dermatomyositis: report of a case. *Dis Colon Rectum* 2008; 51: 474-6.
- Jarrot PA, Dury S, Rakotomalala A, et al. Association of sarcoidosis and ulcerative colitis: a review of 20 cases. *Sarcoidosis Vasc Diffuse Lung Dis* 2013; 30: 212-6.
- Allele Frequencies in Worldwide Populations: <http://www.allele-frequencies.net/hla6003a.asp>
- Ishihara M, Ohno S, Ishida T, et al. Molecular genetic studies of HLA class II alleles in sarcoidosis. *Tissue Antigens* 1994; 43: 238-41.
- Satsangi J, Welsh KI, Bunce M, et al. Contribution of genes of the major histocompatibility complex to susceptibility and disease phenotype in inflammatory bowel disease. *Lancet* 1996; 347: 1212-7.
- Asano K, Matsushita T, Umeno J, et al. A genome-wide association study identifies three new susceptibility loci for ulcerative colitis in the Japanese population. *Nat Genet* 2009; 41: 1325-9.
- Camus P, Colby TV. The lung in inflammatory bowel disease. *Eur Respir J* 2000; 15: 5-10.
- Black H, Mendoza M, Murin S. Thoracic manifestations of inflammatory bowel disease. *Chest* 2007; 131: 524-32.
- Franco AI, Escobar L, García XA, et al. Mesalazine-induced eosinophilic pneumonia in a patient with ulcerative colitis disease: a case report and literature review. *Int J Colorectal Dis* 2016; 31: 927-9.